



Hospital Universitario
Puerta de Hierro
Majadahonda



FUNDACIÓN PARA LA INVESTIGACIÓN
BIOMÉDICA
Hospital Universitario Puerta de Hierro Majadahonda



VIEDITION INTERNATIONAL **ESD LIVE MADRID 2019** **CLINICAL & HANDS-ON COURSE**

SEPT 30th - OCT 1st / 2019

Puerta de Hierro University Hospital Majadahonda - Madrid

VEDITATION
INTERNATIONAL
ESD LIVE MADRID 2019
CLINICAL & HANDS-ON COURSE

SEPT 30th - OCT 1st / 2019

LIVE CASES

Monday 30th



Hospital Universitario
Puerta de Hierro
Majadahonda

Morning list

Monday 30th

Case 7

Endoscopist: Yamamoto

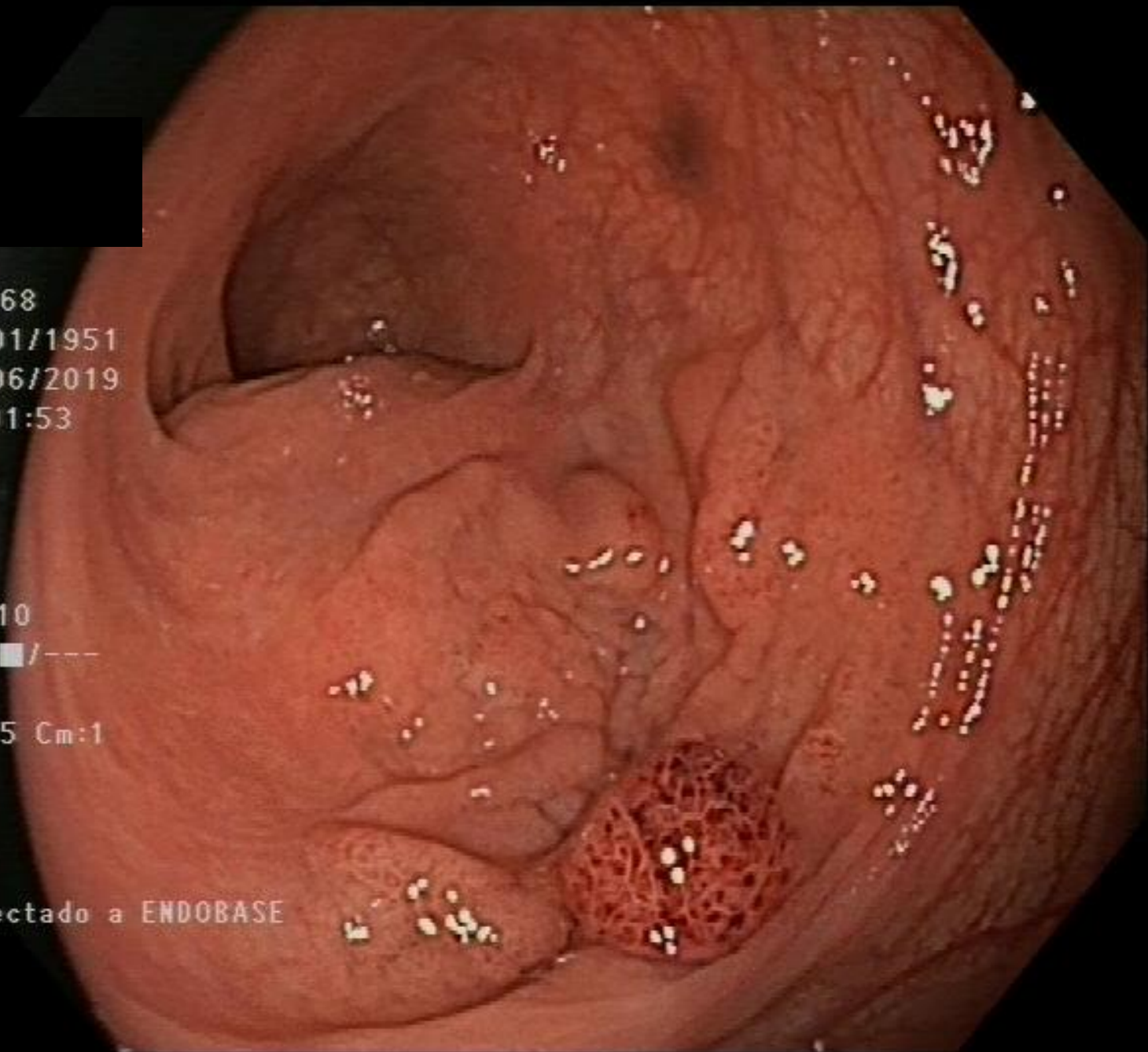
Room 271

- 68yo male
HTN. Appendectomy.
- **LST granular mixed-type (0-IIa+Is)**
 - Estimated Lesion size: 40mm
 - Location: Sigmoid colon
 - No signs of deep submucosal invasión
- **Aim:** For en-bloc ESD attempt

M 68
29/01/1951
10/06/2019
18:01:53

D.F:10
■■■/---
0/1
Eh:A5 Cm:1

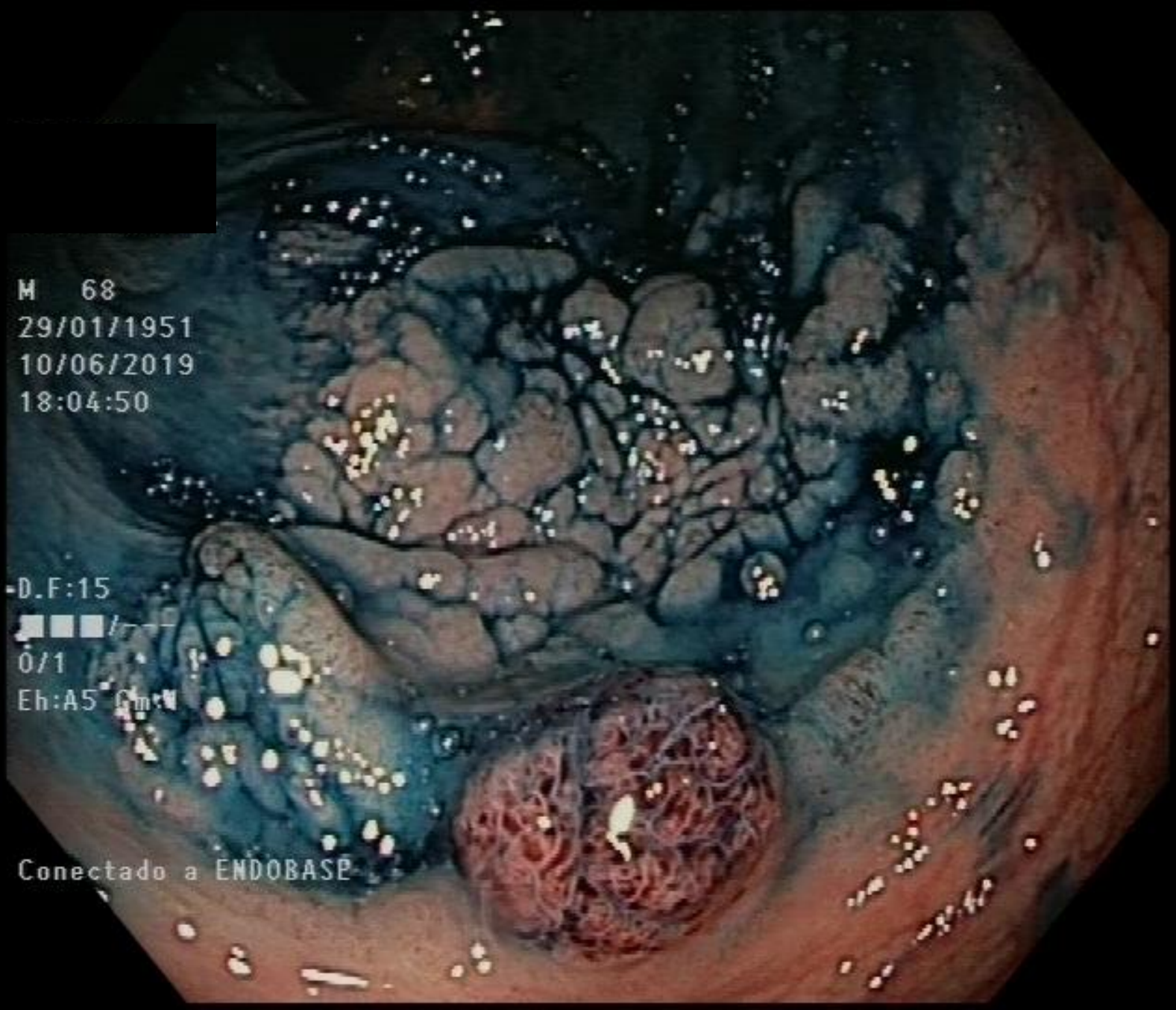Conectado a ENDOBASE



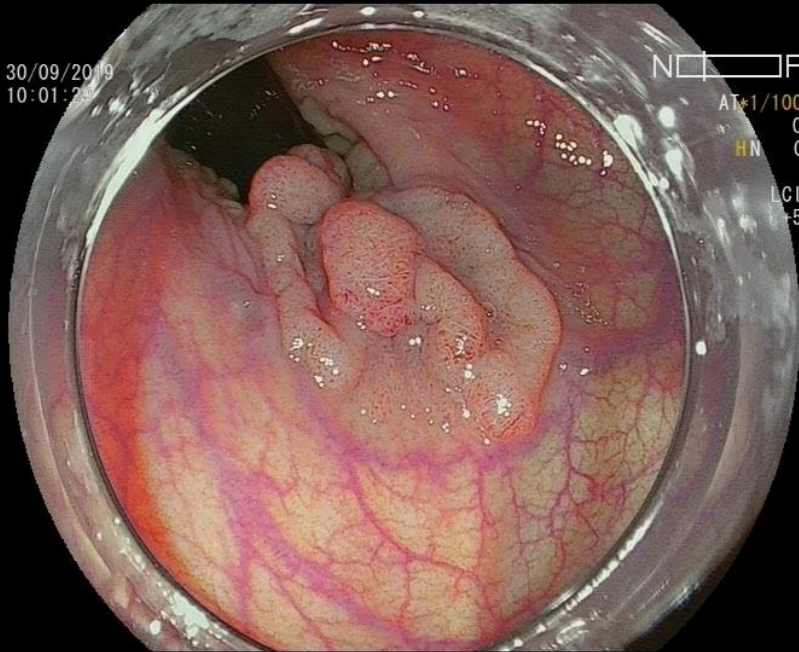
M 68
29/01/1951
10/06/2019
18:04:50

D.F:15
■■■/—
0/1
Eh:A5 Cm

Conectado a ENDOBASÉ

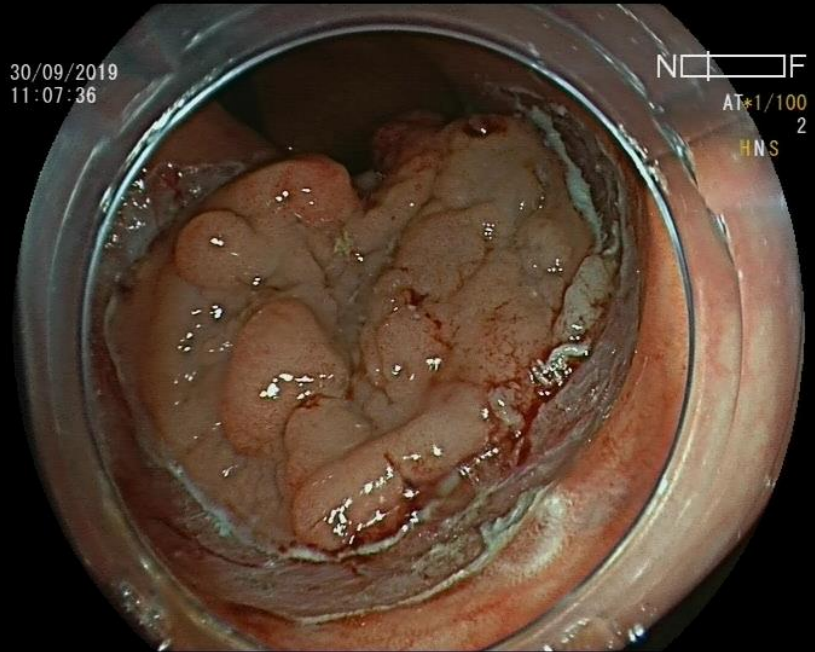


30/09/2019
10:01:23



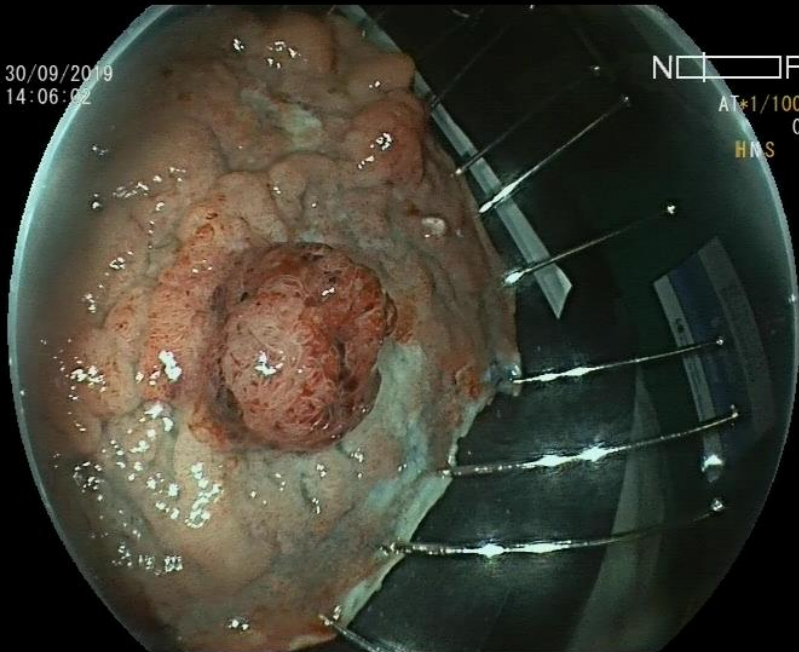
NO [] F
AT*1/100
0
HN C
LCI
+5

30/09/2019
11:07:36



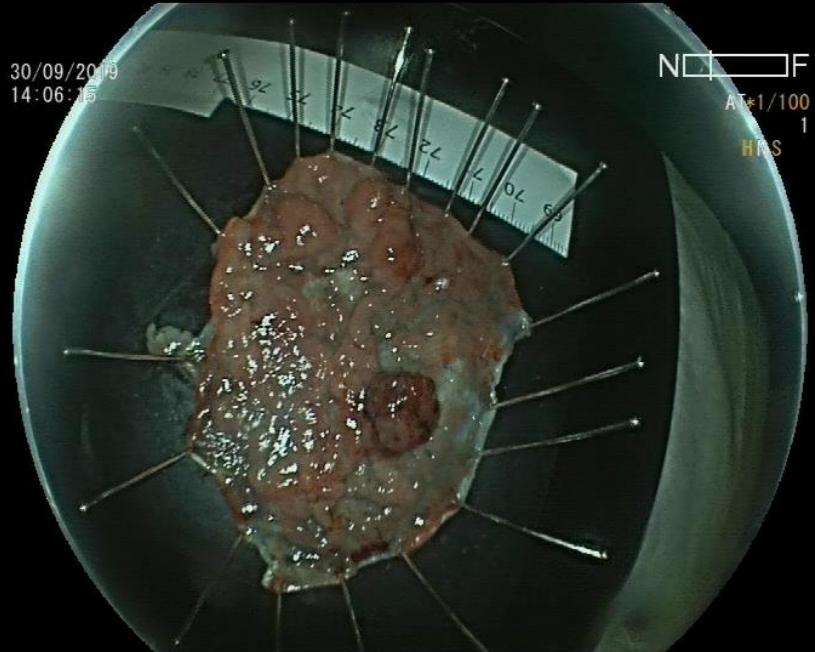
NO [] F
AT*1/100
2
HNS

30/09/2019
14:06:02



NO [] F
AT*1/100
0
HNS

30/09/2019
14:06:15



NO [] F
AT*1/100
1
HNS

Pathology report



TUBULOVILLOUS ADENOMA


- ESD specimen dimensions: 60 x 50 x 1 mm
- Lesion size: 52 x 45 x 6 mm
- OMS: High grade dysplasia (3mm)
- Vienna: Category 4
- Non pedunculated
- Margin: LM + (R1) with LGD

Case 4

Endoscopist: Maeda

Room 272

- 70yo male
Asthma, obstructive sleep apnea
Atrophic gastritis with extensive intestinal metaplasia
- **Flat-depressed lesion (0-II+IIc) in the stomach**
 - Estimated Lesion size: 20mm
 - Location: incisura angularis
 - Biopsy: HGD/intramucosal cancer
 - EUS & CT scan: cT1N0.
- **Aim:** For en-bloc ESD attempt



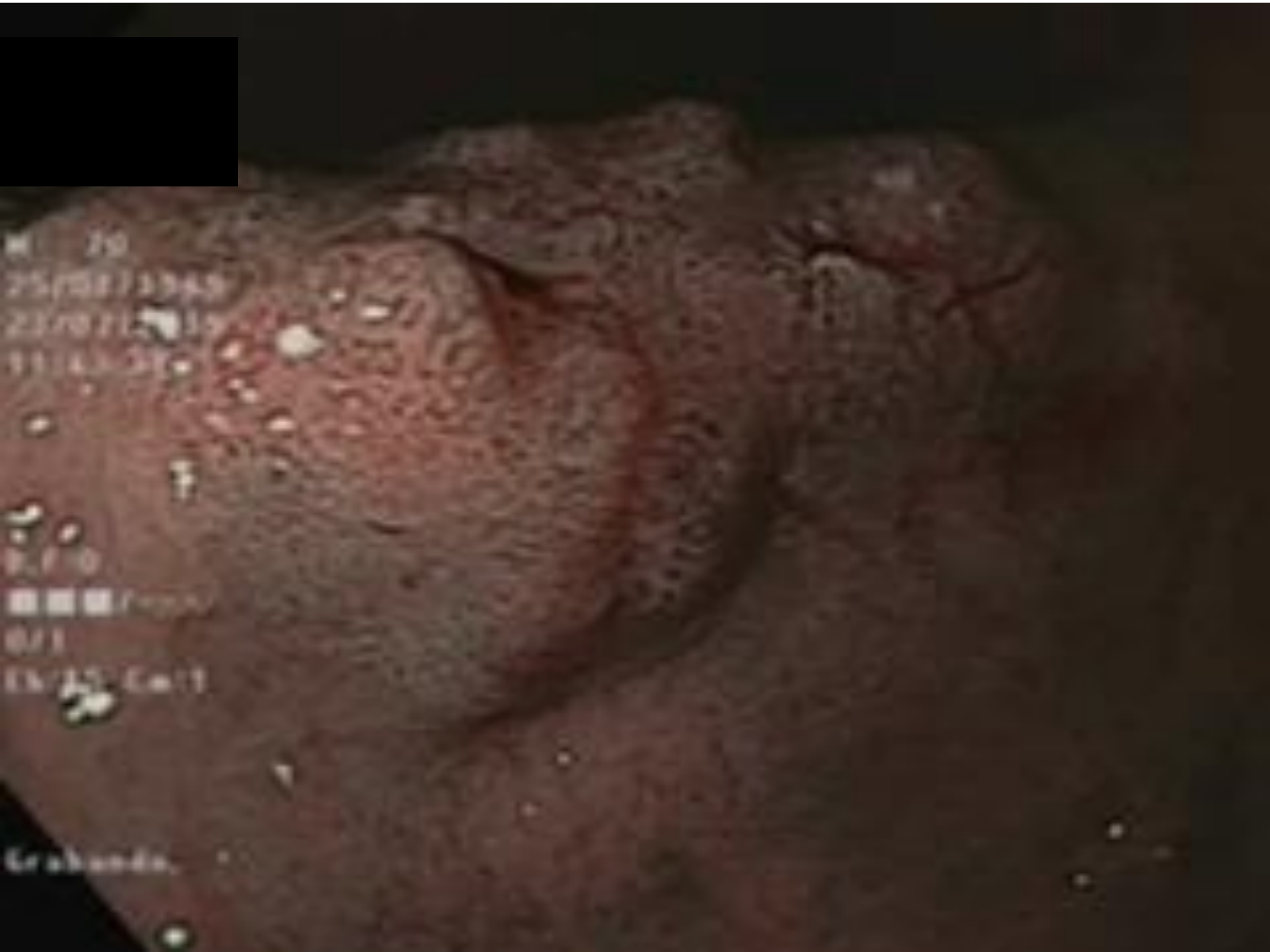
M 70
25/08/1950
23/07/20
13/6/20

6ra



W 70
2570373345
2370 21 15
11143 21
B.F. 0
0/1
EN 15 Cell

Crabapple



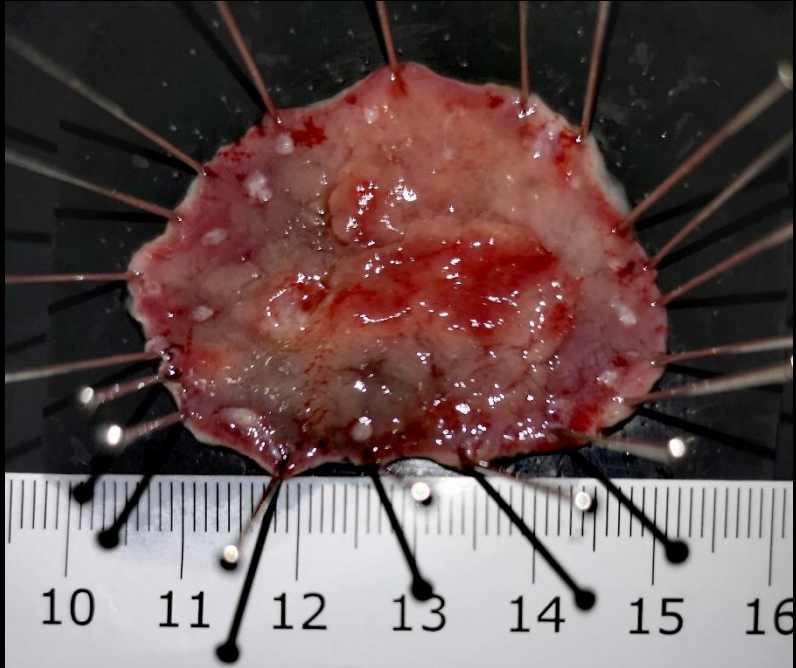
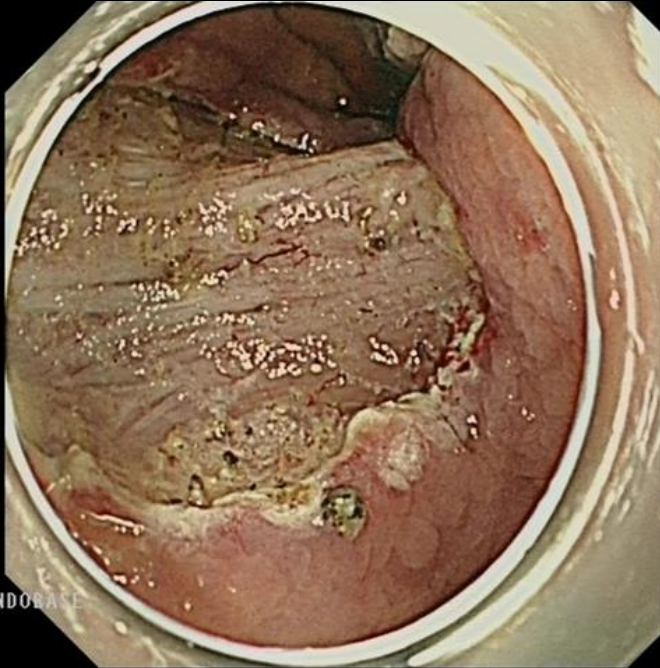
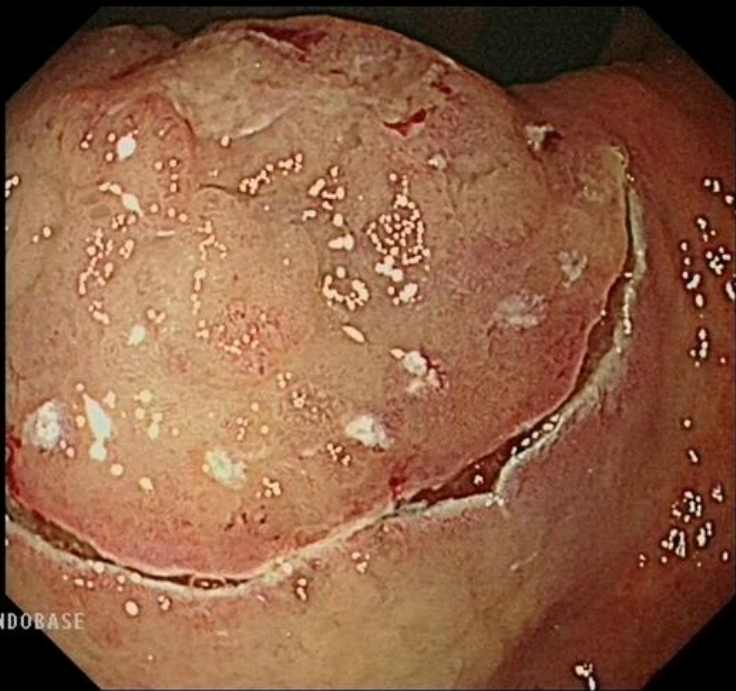
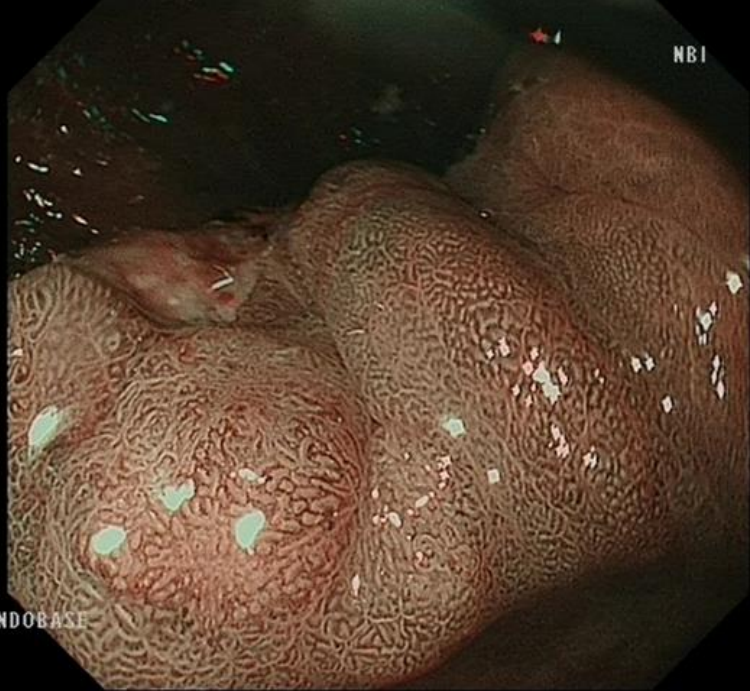
NBI

ENDOBASE

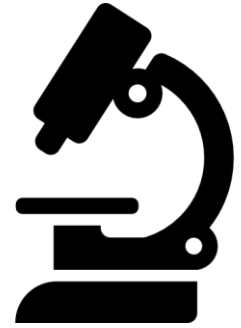ENDOBASE

ENDOBASE

10 11 12 13 14 15 16



Pathology report



ATROPHIC GASTRITIS AND LOW GRADE DYSPLASIA WITH FOCAL AREAS OF HIGH GRADE DYSPLASIA

- ESD specimen dimensions: 4,5 x 3,8 x 0,2 cm
- Lesion size: 32 x 20 x 2 mm
- OMS: High grade dysplasia
- Vienna: Category 4
- Non pedunculated
- Margin: R0 LM-

Afternoon list

Monday 30th

Case 10

Endoscopist: Toyonaga

Room 271

- 81yo male

HTN, DM. Ischemic heart disease (4 coronary stents in 2011) on Aspirin. Chronic kidney disease.

Sessile lesion (0-Is)

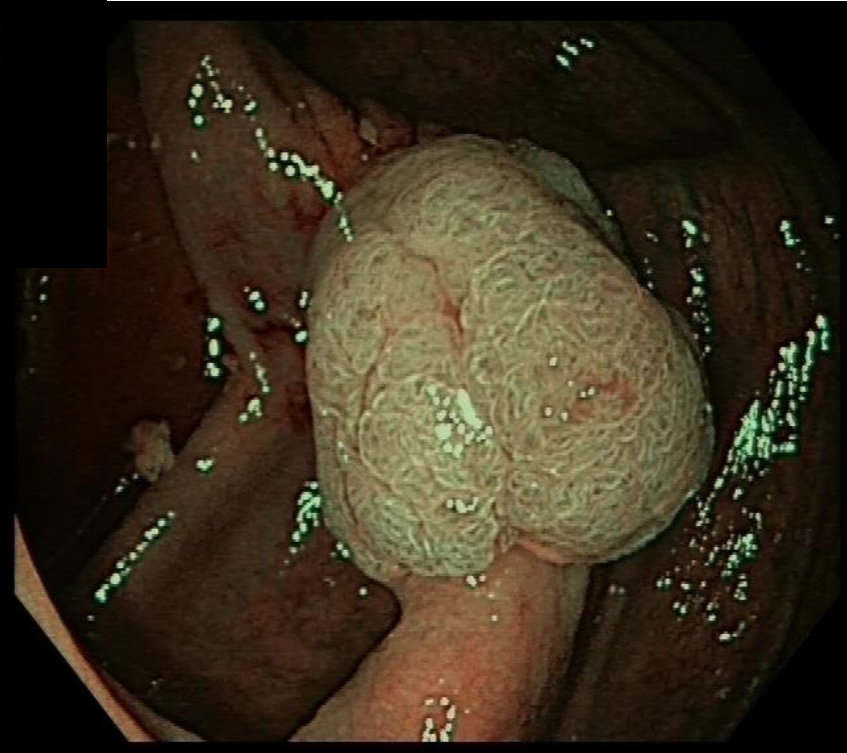
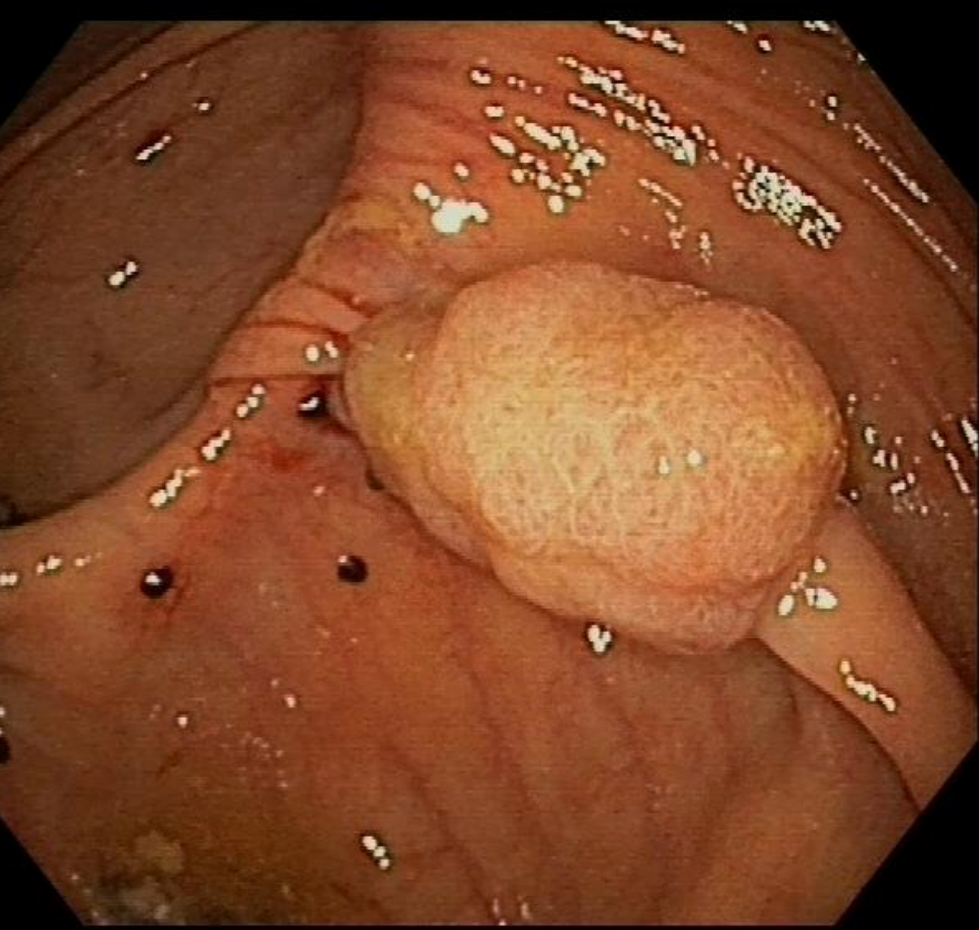- Estimated Lesion size: 25mm
- Location: Cecum
- No signs of deep submucosal invasión

Aim: For en-bloc EMR/ESD attempt

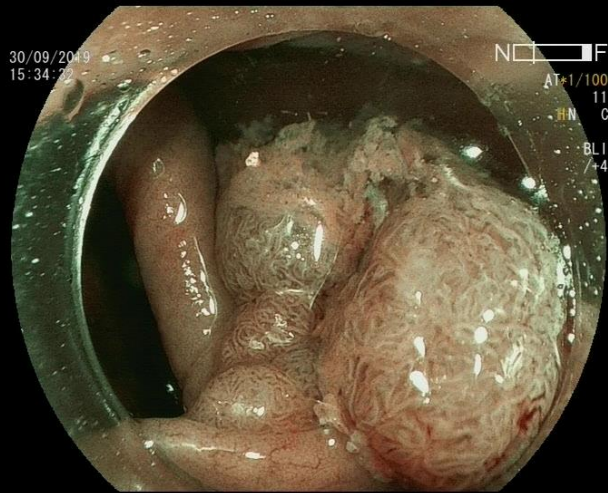
LST granular homogeneous-type (0-IIa)

- Estimated Lesion size: 30-35mm
- Location: Distal transverse colon
- No signs of deep submucosal invasion

Aim: For en-bloc ESD attempt

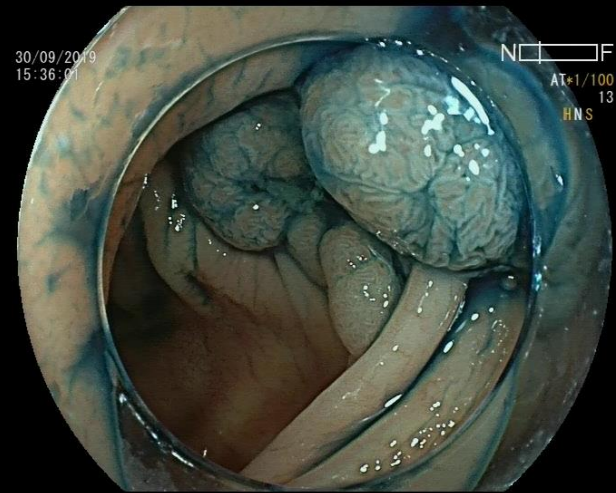


30/09/2019
15:34:39

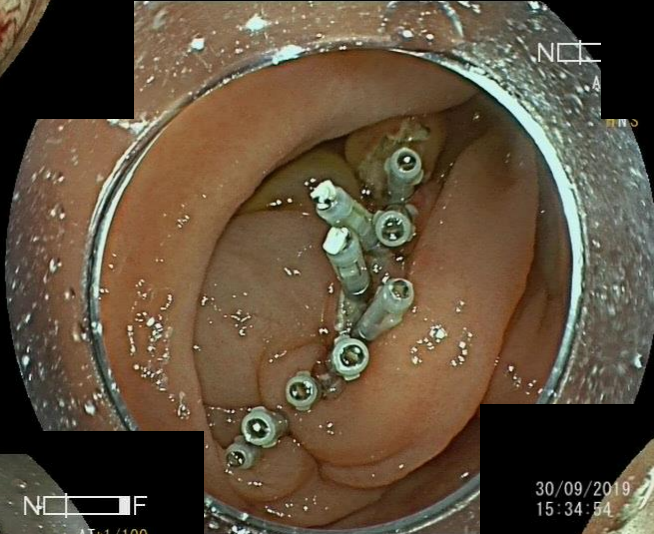


N F
AT*1/100
11
HN C
BLI
/+4

30/09/2019
15:36:01

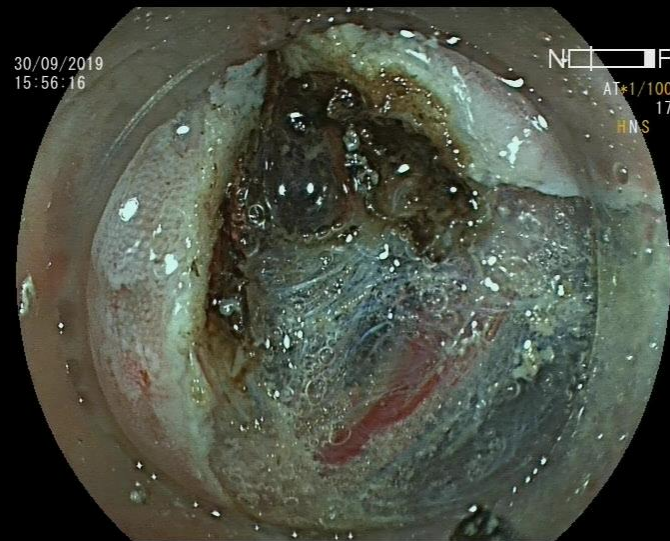

N F
AT*1/100
13
HNS



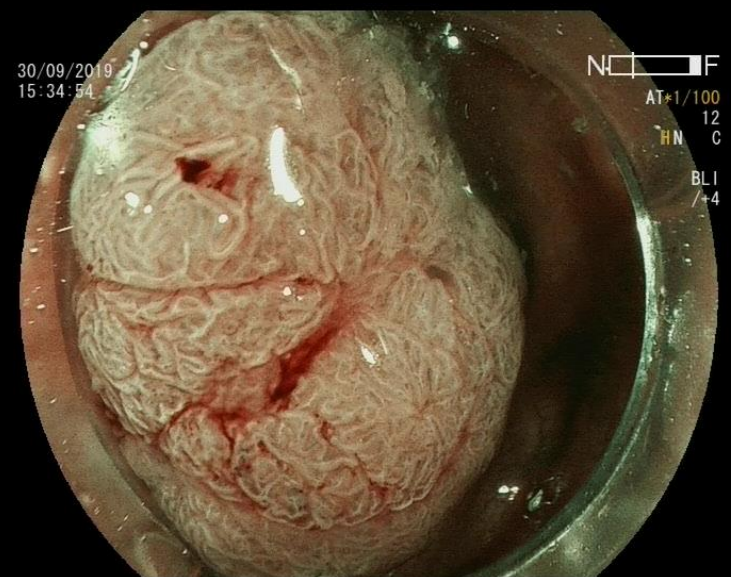
N F
A
HN

30/09/2019
15:56:16



N F
AT*1/100
17
HNS

30/09/2019
15:34:54



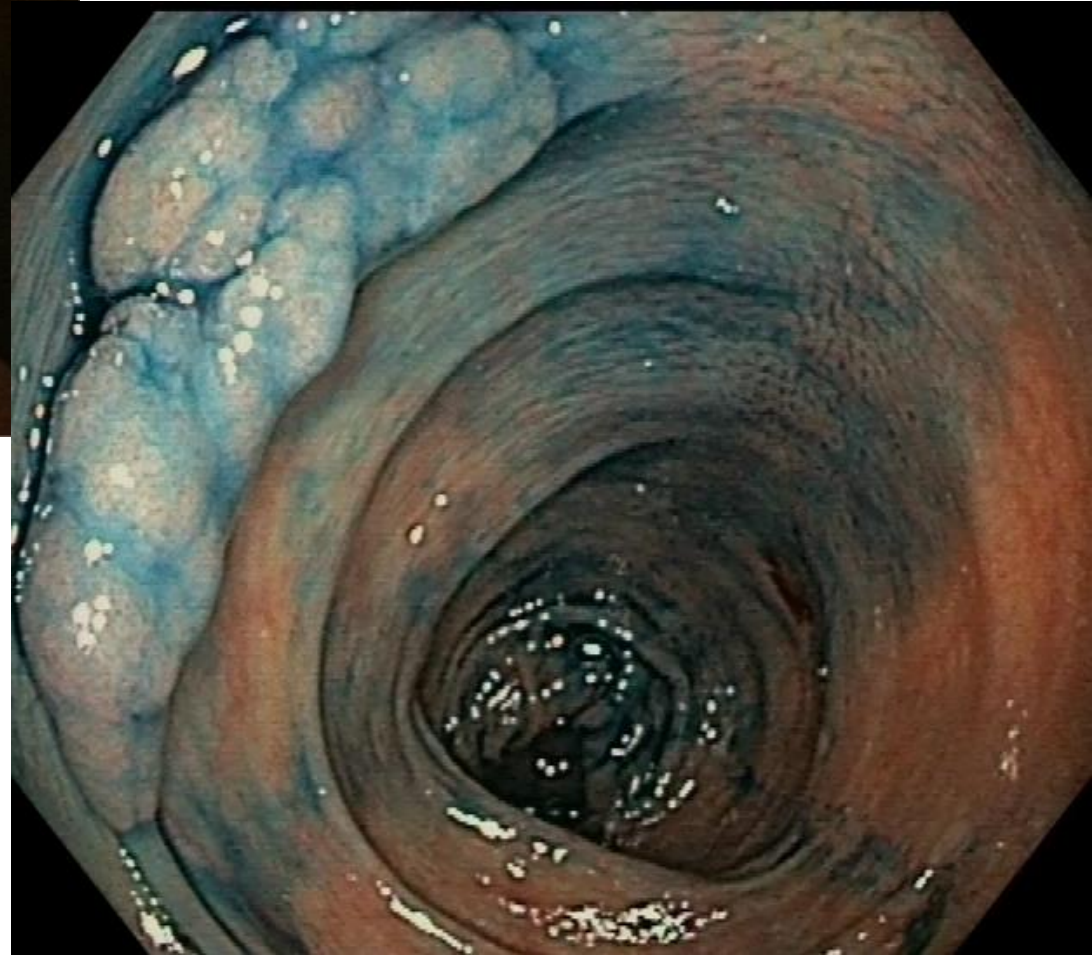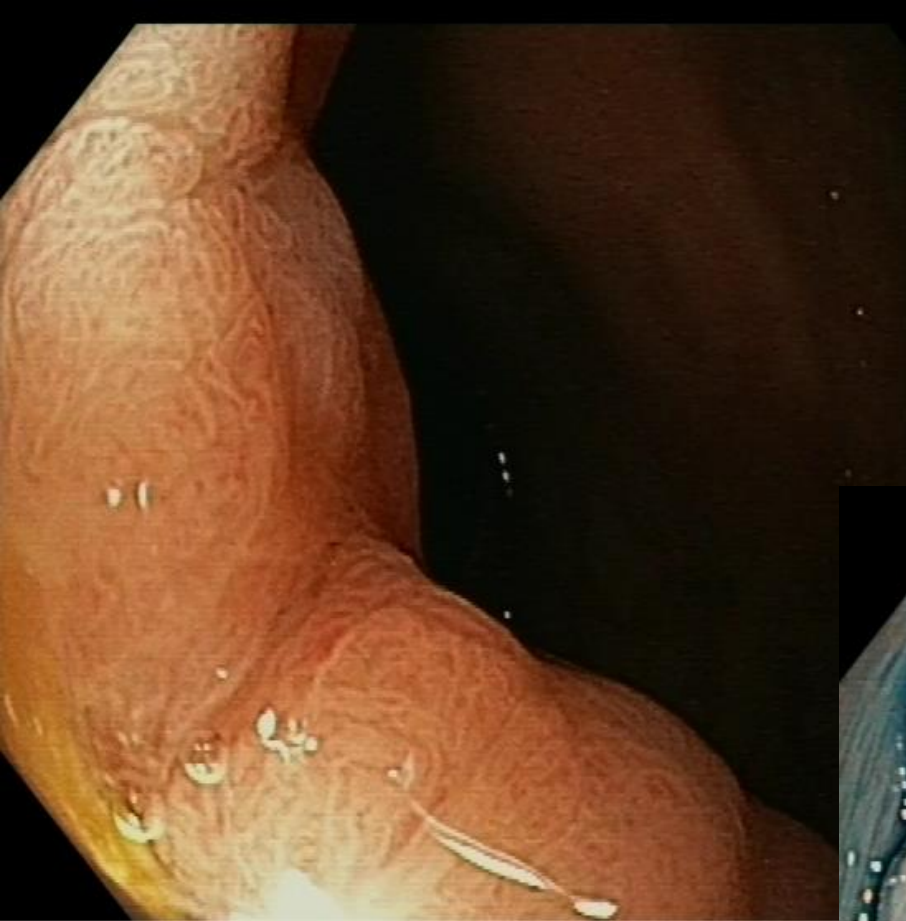
N F
AT*1/100
12
HN C
BLI
/+4

Pathology report



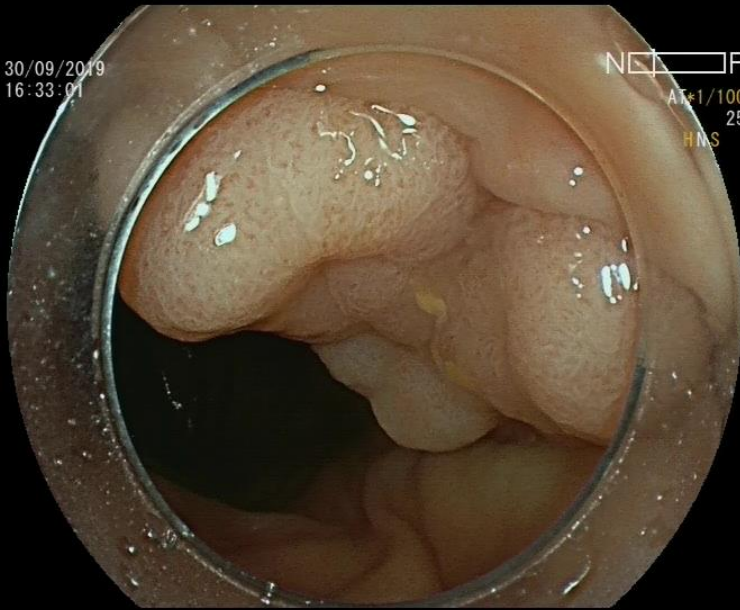
TUBULOVILLOUS ADENOMA

- ESD specimen dimensions: 45 x 40 x 10 mm
- Lesion size: 34 x 30 x 8 mm
- OMS: Low grade dysplasia
- Vienna: Category 3
- Non pedunculated
- Margin: R0 LM-



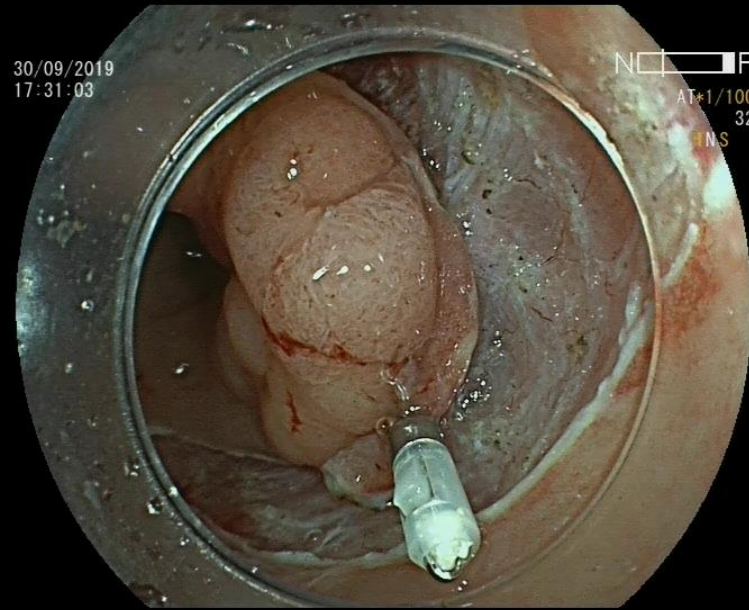
30/09/2019
16:33:01

N F
AT*1/100
25
HNS



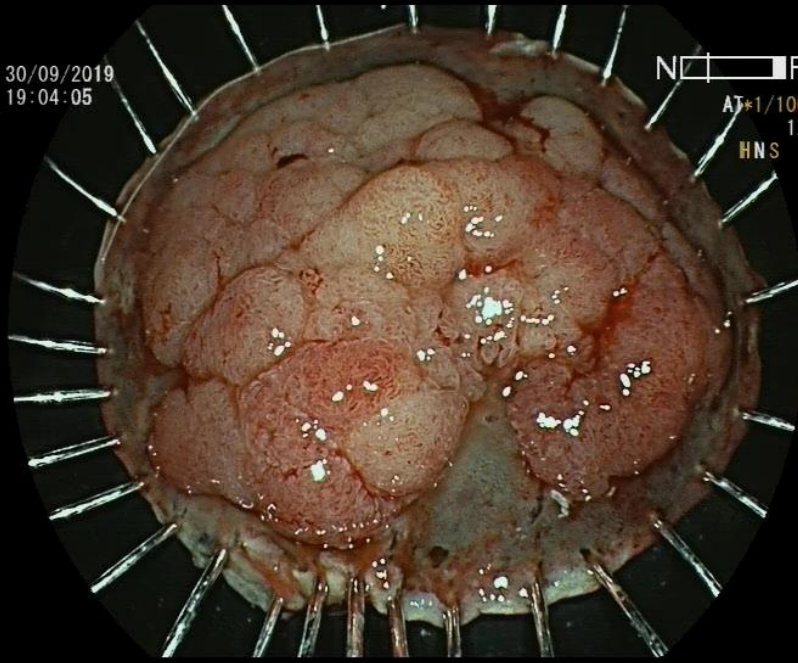
30/09/2019
17:31:03

N F
AT*1/100
32
HNS



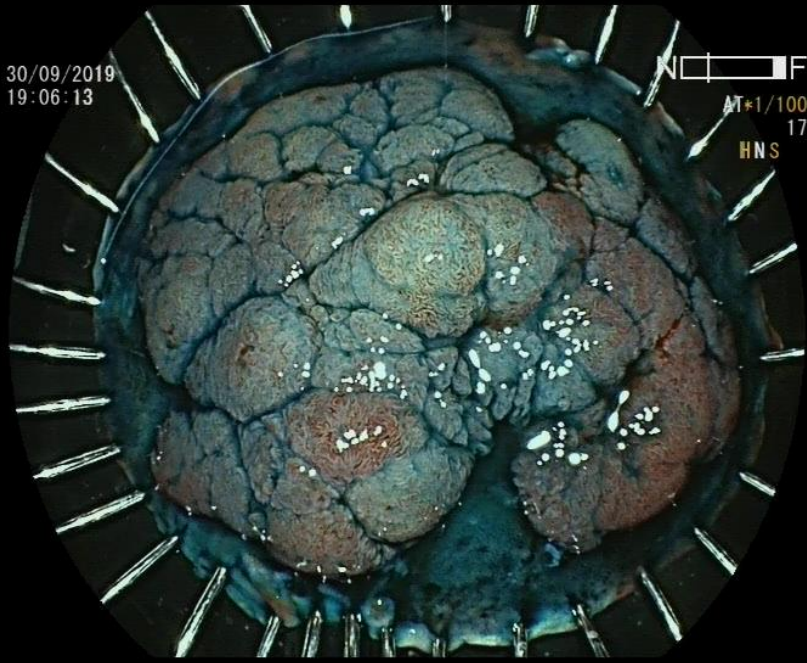
30/09/2019
19:04:05

N F
AT*1/100
12
HNS



30/09/2019
19:06:13

N F
AT*1/100
17
HNS



Pathology report



TUBULOVILLOUS ADENOMA

- ESD specimen dimensions: 47 x 35 x 10 mm
- Lesion size: 34 x 30 x 8 mm
- OMS: Low grade dysplasia
- Vienna: Category 3
- Non pedunculated
- Margin: R0 LM-

Case 9

Endoscopist: Piessevaux

Room 272

- 80yo female
HTN, stroke on Clopidogrel (bridge therapy with Aspirin prescribed)
- **Sessile lesion (0-Is)**
 - Estimated Lesion size: 35mm
 - Location: sigmoid colon
 - No signs of deep submucosal invasion
- **Aim:** For en-bloc ESD attempt

NBI

08/08/2019

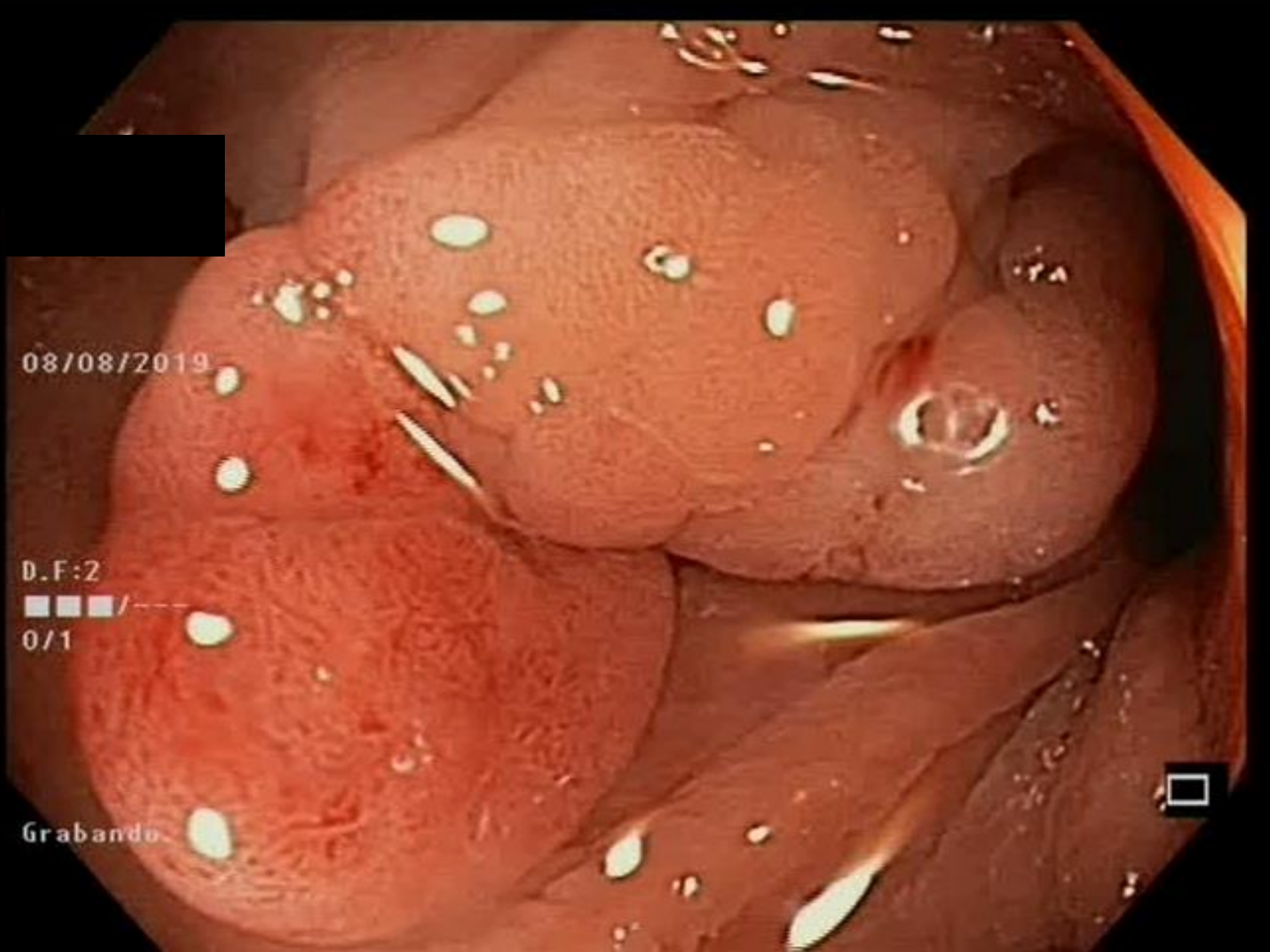
D.F:2



0/1

Grabando.





08/08/2019

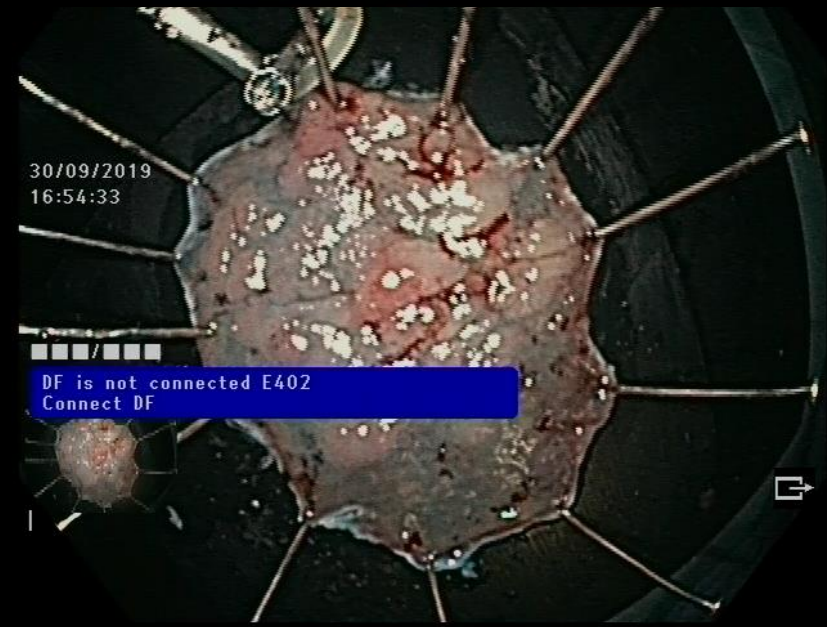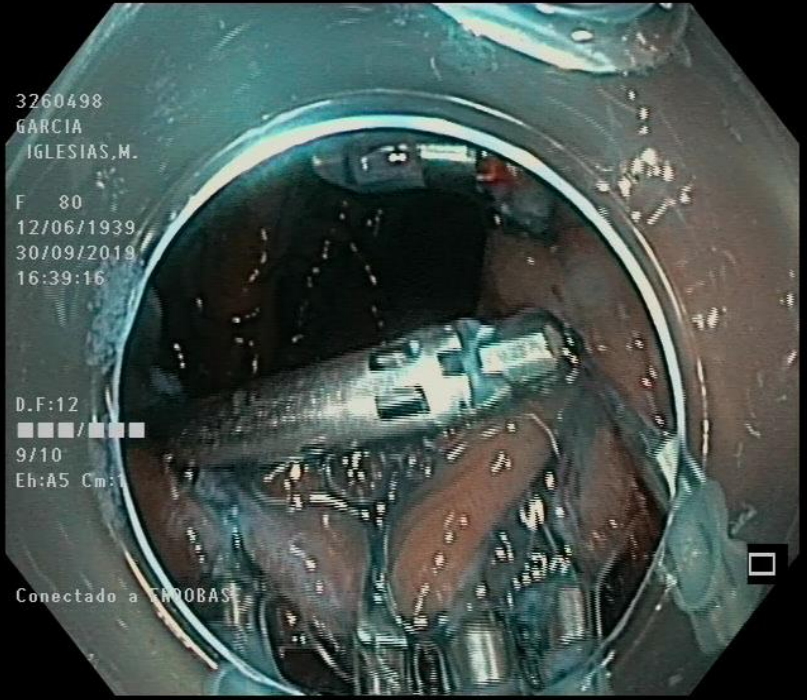
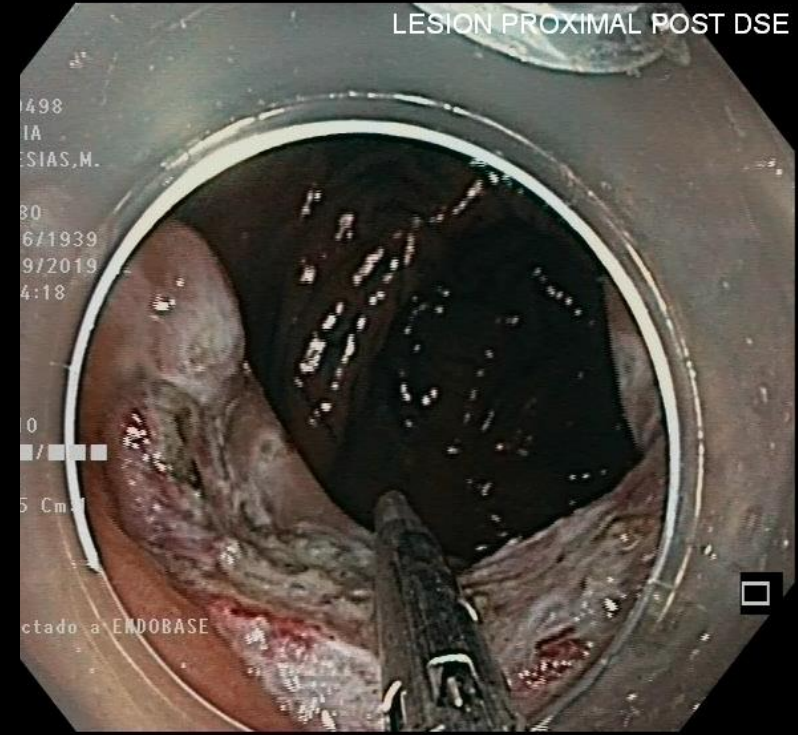
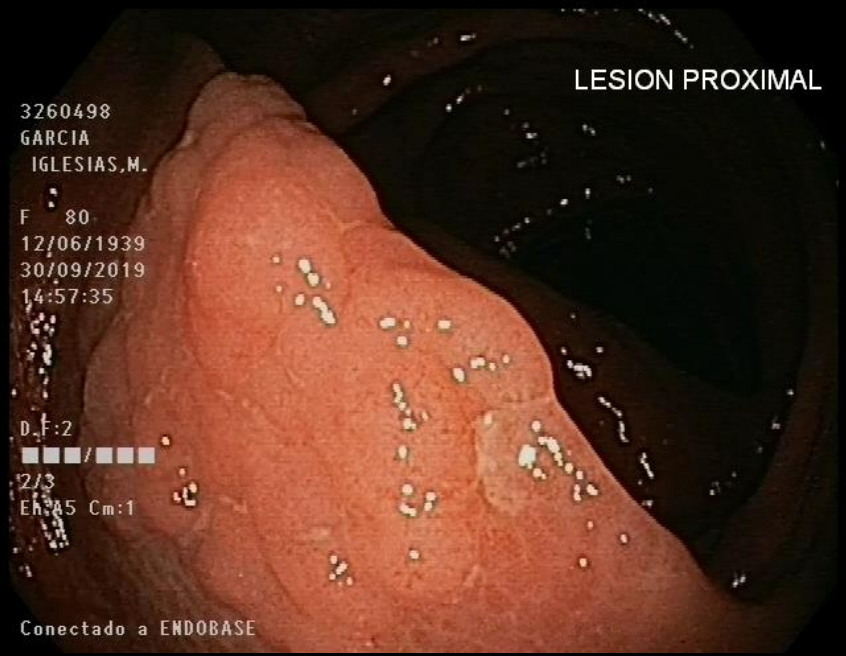D.F:2



0/1

Grabando





Pathology report



TUBULAR ADENOMA

- ESD specimen dimensions: 37 x 32 x 03 mm
- Lesion size: 28 x 20 x 80 x 3 mm
- OMS: Low grade dysplasia
- Vienna: Category 3
- Non pedunculated
- Margin: R0 LM-

VEDITION
INTERNATIONAL
ESD LIVE MADRID 2019
CLINICAL & HANDS-ON COURSE

SEPT 30th - OCT 1st / 2019

LIVE CASES

Tuesday 1st



Hospital Universitario
Puerta de Hierro
Majadahonda

Morning list

Tuesday 1st

Case 1

Endoscopist: Toyonaga

Room 271

- 83yo female
HTN, osteoporosis
- **LST granular mixed-type (0-IIa+Is)**
 - Estimated Lesion size: 80mm
 - Location: rectum from 12 to 4cm from anal verge (affecting 100% of circumference)
 - Residual lesion after previous transanal surgery attempt (another institution)
 - Biopsy: HGD
- **Aim:** For en-bloc ESD attempt

NBI

83

04/01/1936

18/07/2019

11:43:44

D.F:4

■■■■ / ■■■■

0/1

Eh:A5 Cm:1

Grabando.

F. 83
04/01/1936
18/07/2019
11:41:49

D.F:3

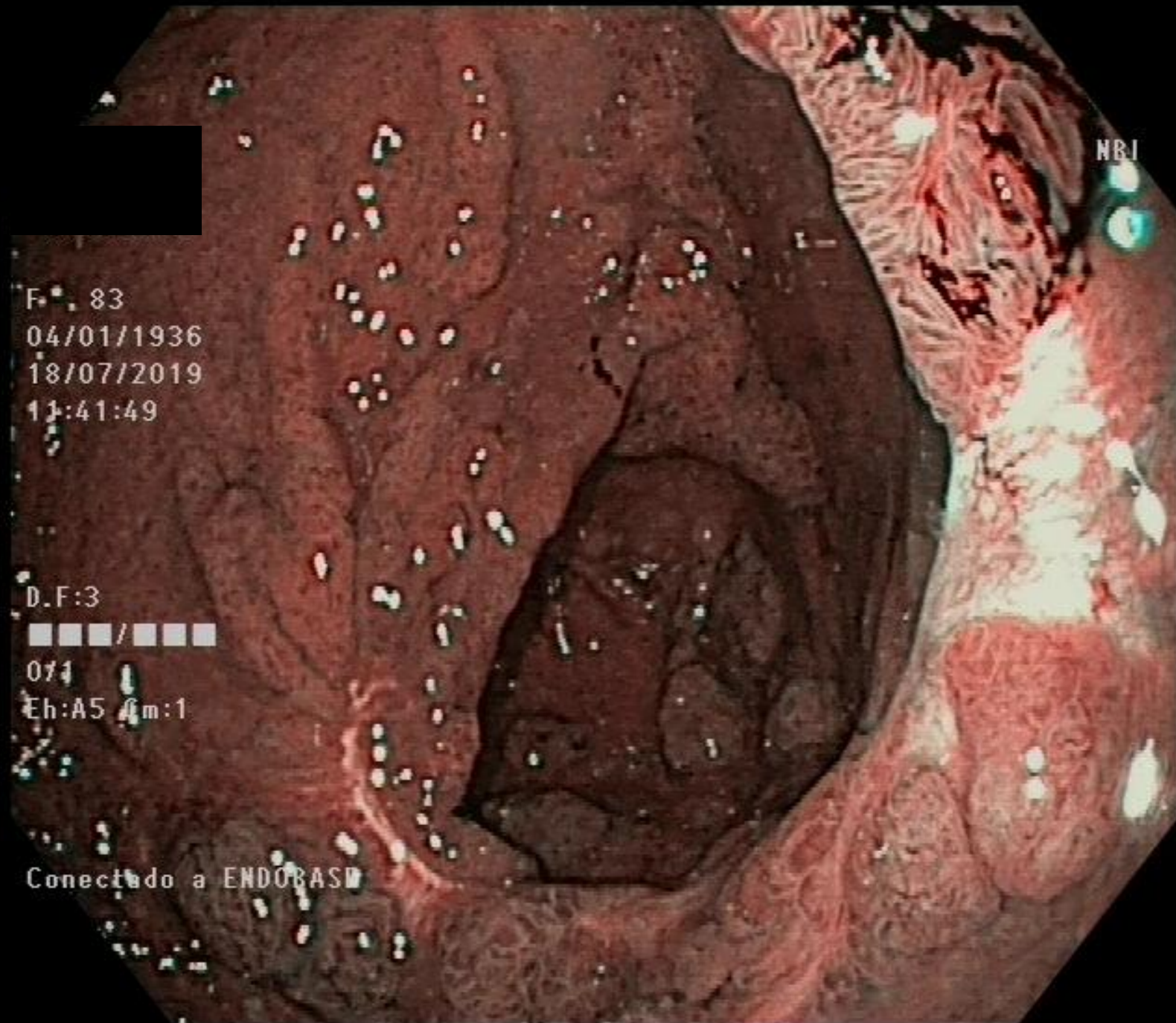

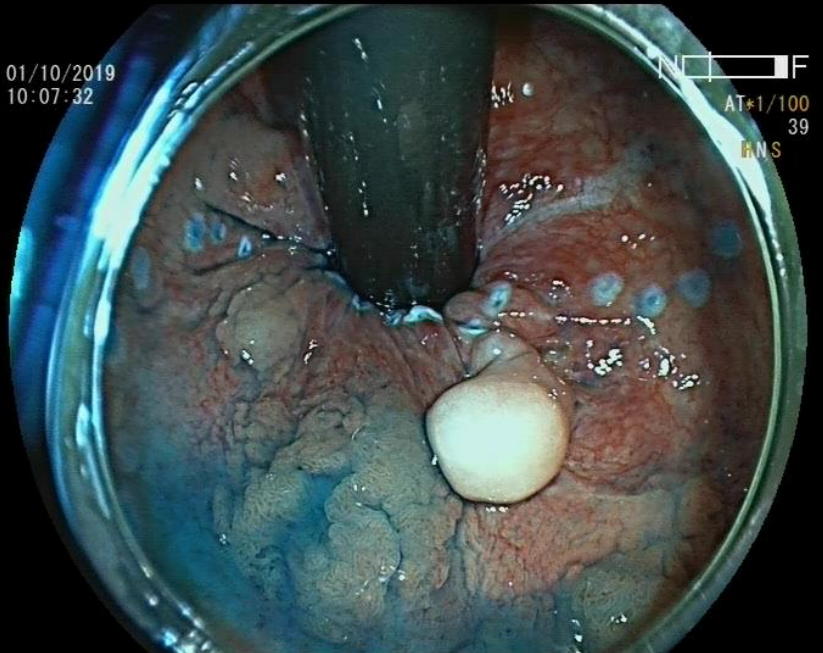
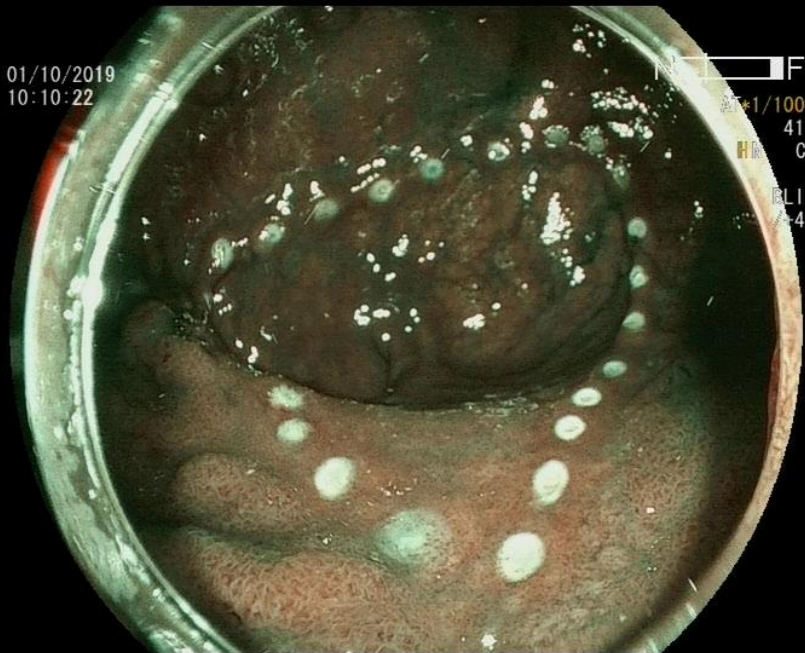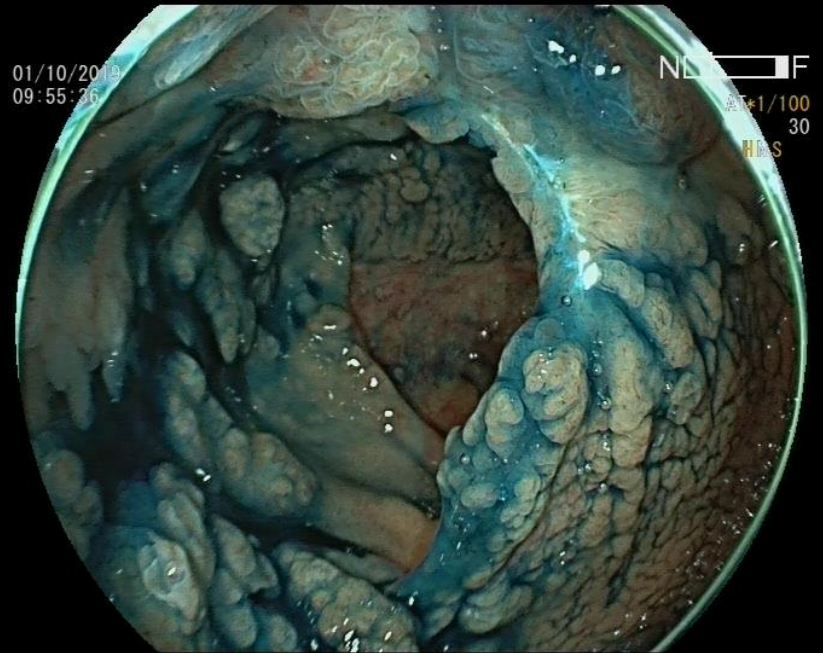
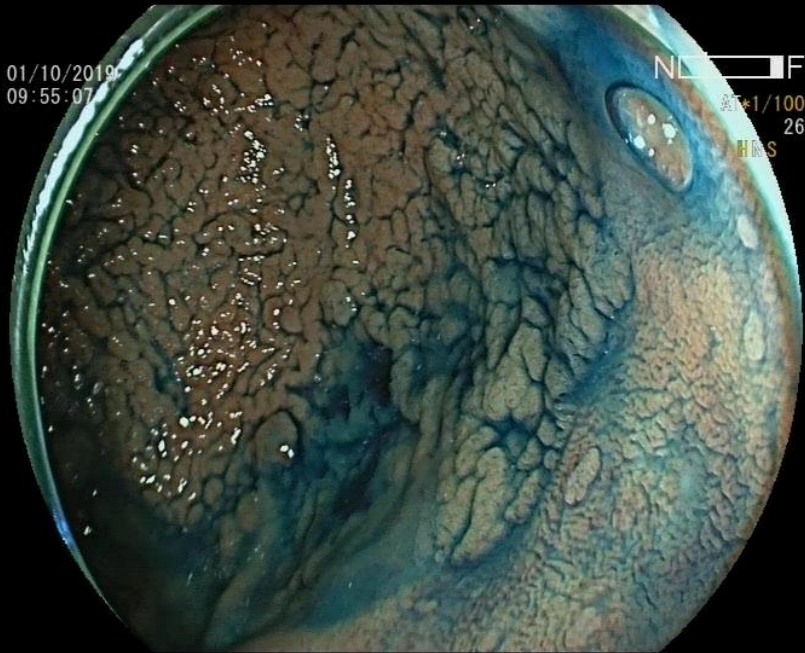
074

Eh:A5 Am:1

Conectado a ENDORASD

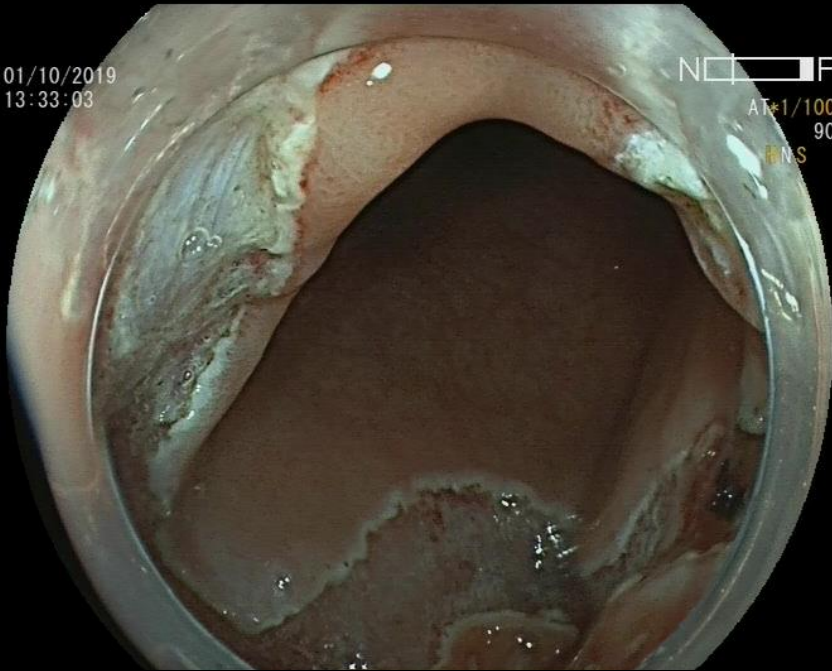
NBI





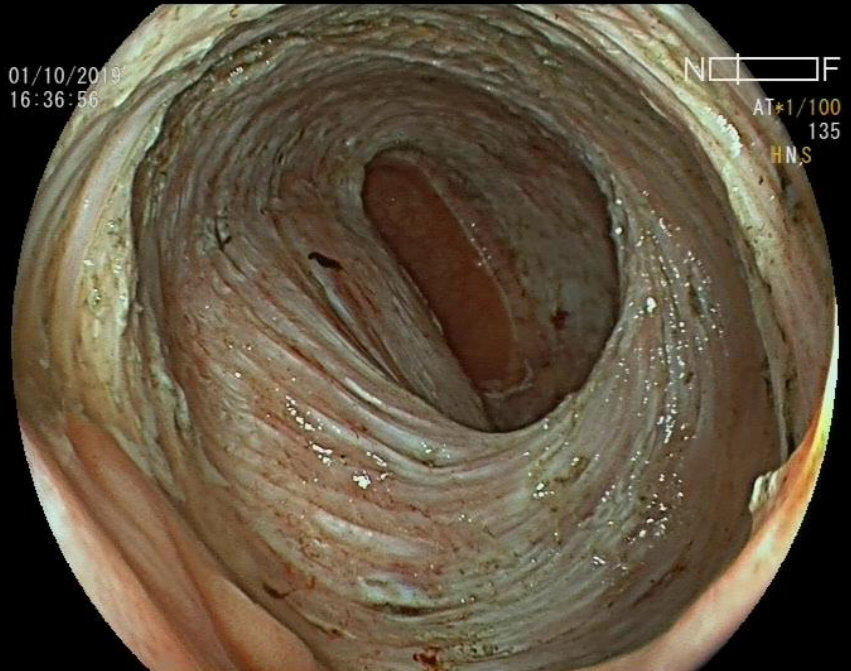
01/10/2019
13:33:03

N F
AT*1/100
90
HNS



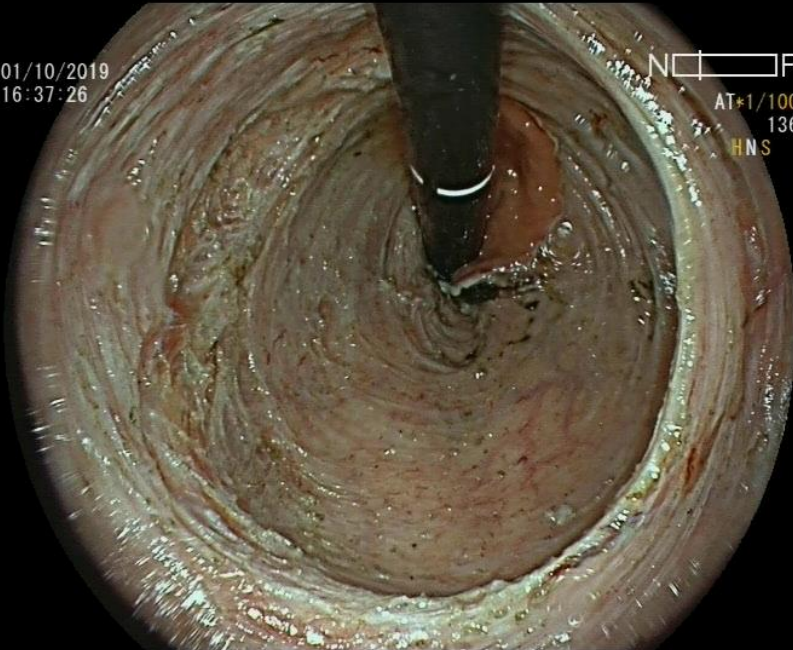
01/10/2019
16:36:56

N F
AT*1/100
135
HNS



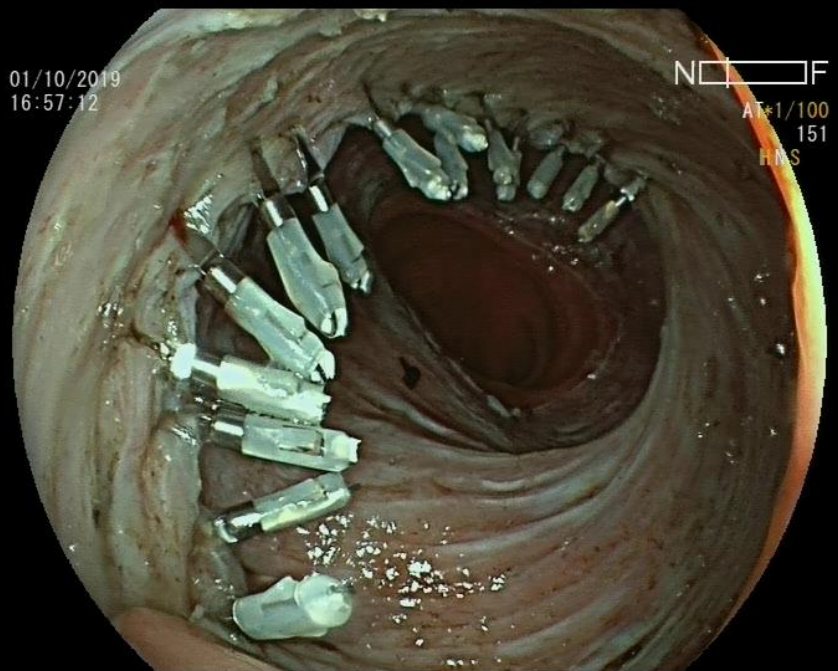
01/10/2019
16:37:26

N F
AT*1/100
136
HNS



01/10/2019
16:57:12

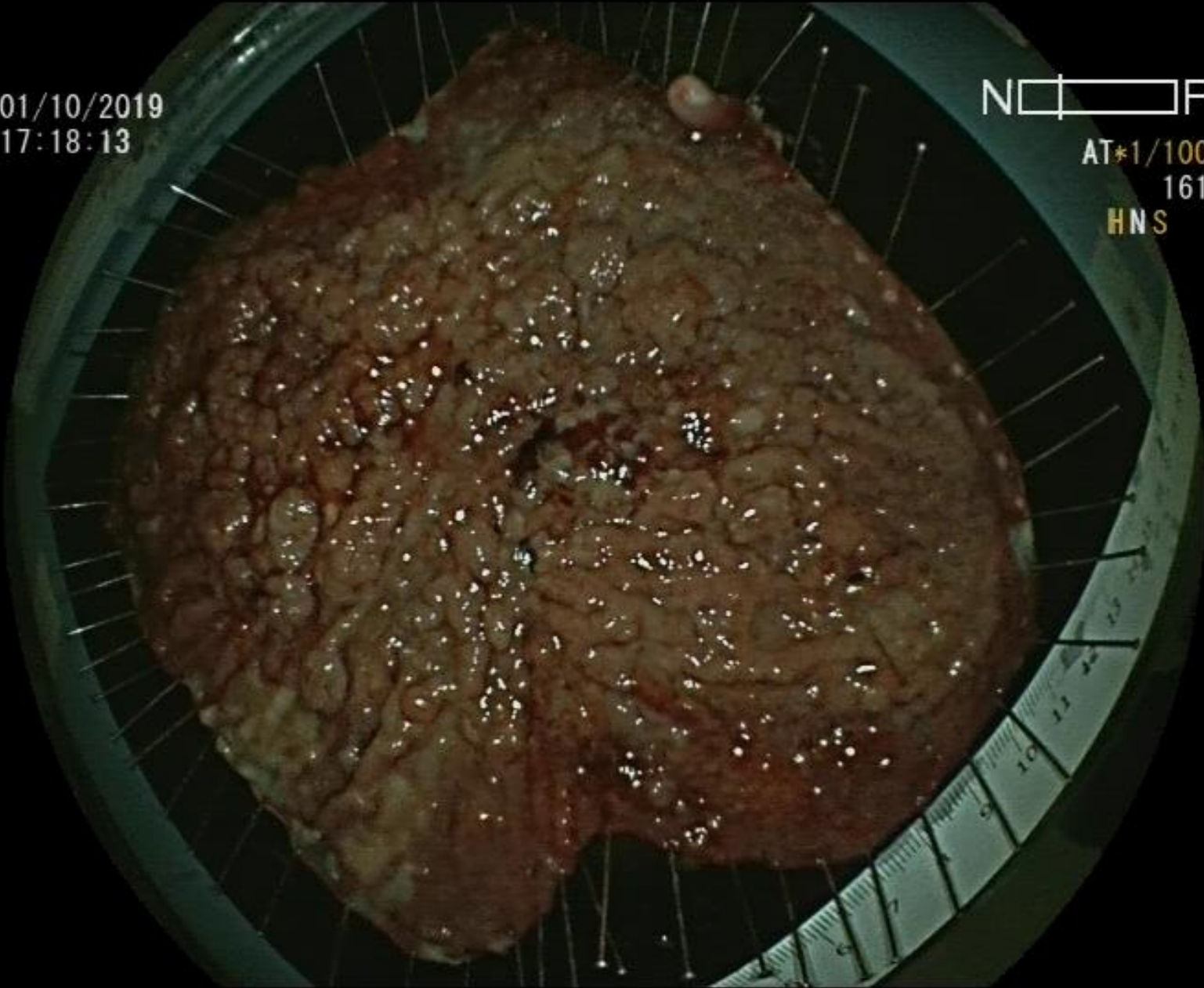
N F
AT*1/100
151
HNS



01/10/2019
17:18:13

N O F

AT*1/100
161
HNS



Pathology report



TUBULO-VILLOUS ADENOMA

- ESD specimen dimensions: 155 x 130 x 10 mm
- Lesion size: 105 x 90 x 8 mm
- OMS: low grade dysplasia
- Vienna: Category 3
- Non pedunculated
- Margin: **LM+ (LGD)**
- **Include a fibroepithelial polyp 7mm**

Case 2

Endoscopist: Piessevaux

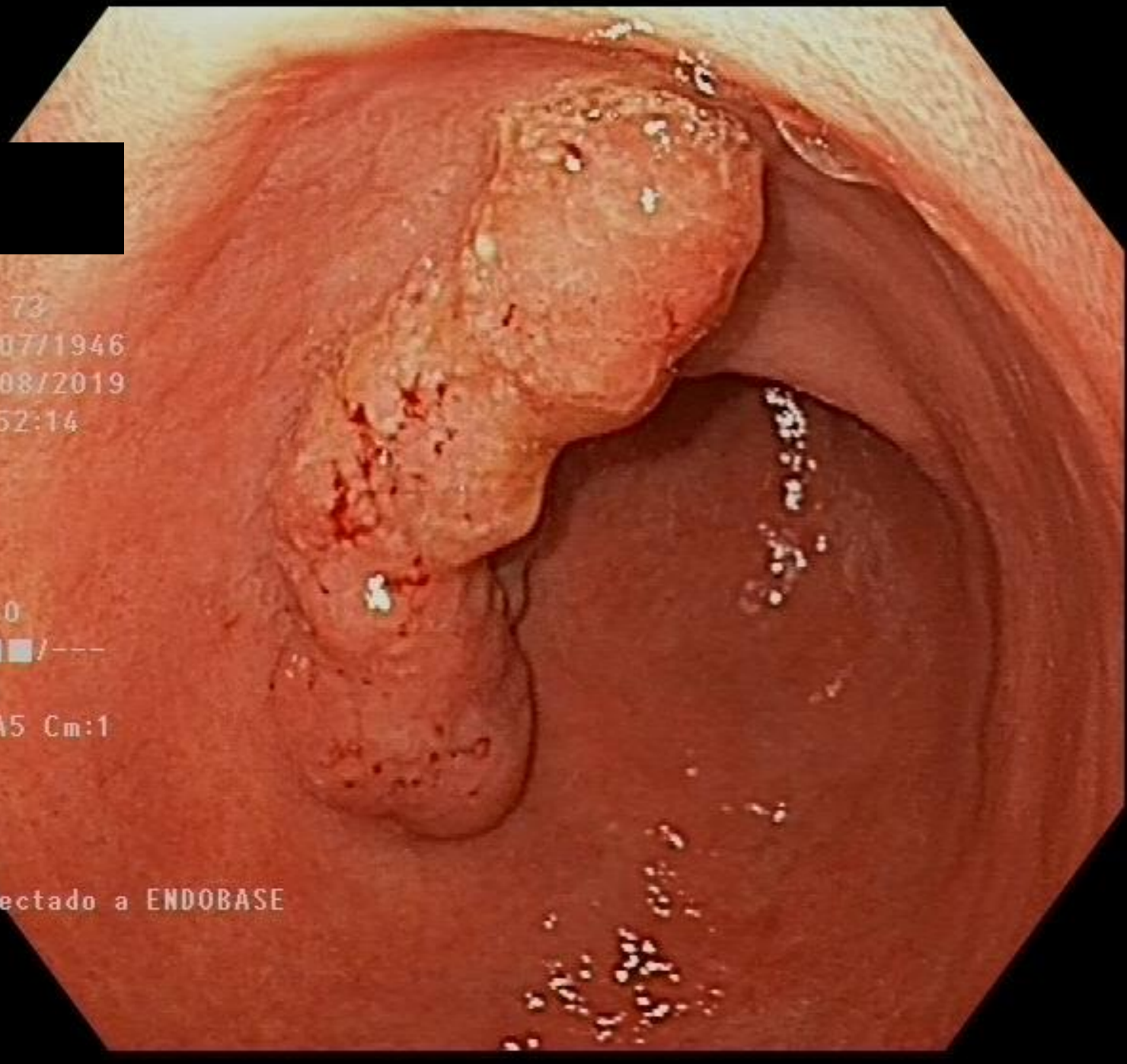
Room 272

- 73yo female
Atrophic gastritis with extensive intestinal metaplasia.
H pylori: negative (no previous treatments)
Family history: Father with gastric cancer
- **Sessile lesion (0-Is) in the stomach**
 - Estimated Lesion size: 35mm
 - Location: Gastric antrum
 - Biopsy: low-grade dysplasia
 - EUS: uT1N0. Periportal 15mm lymph-node, FNA negative for malignancy.
- **Aim:** For en-bloc ESD attempt

F 73
30/07/1946
13/08/2019
08:52:14

D.E:0
■■■/---
0/1
Eh:A5 Cm:1

Conectado a ENDOBASE

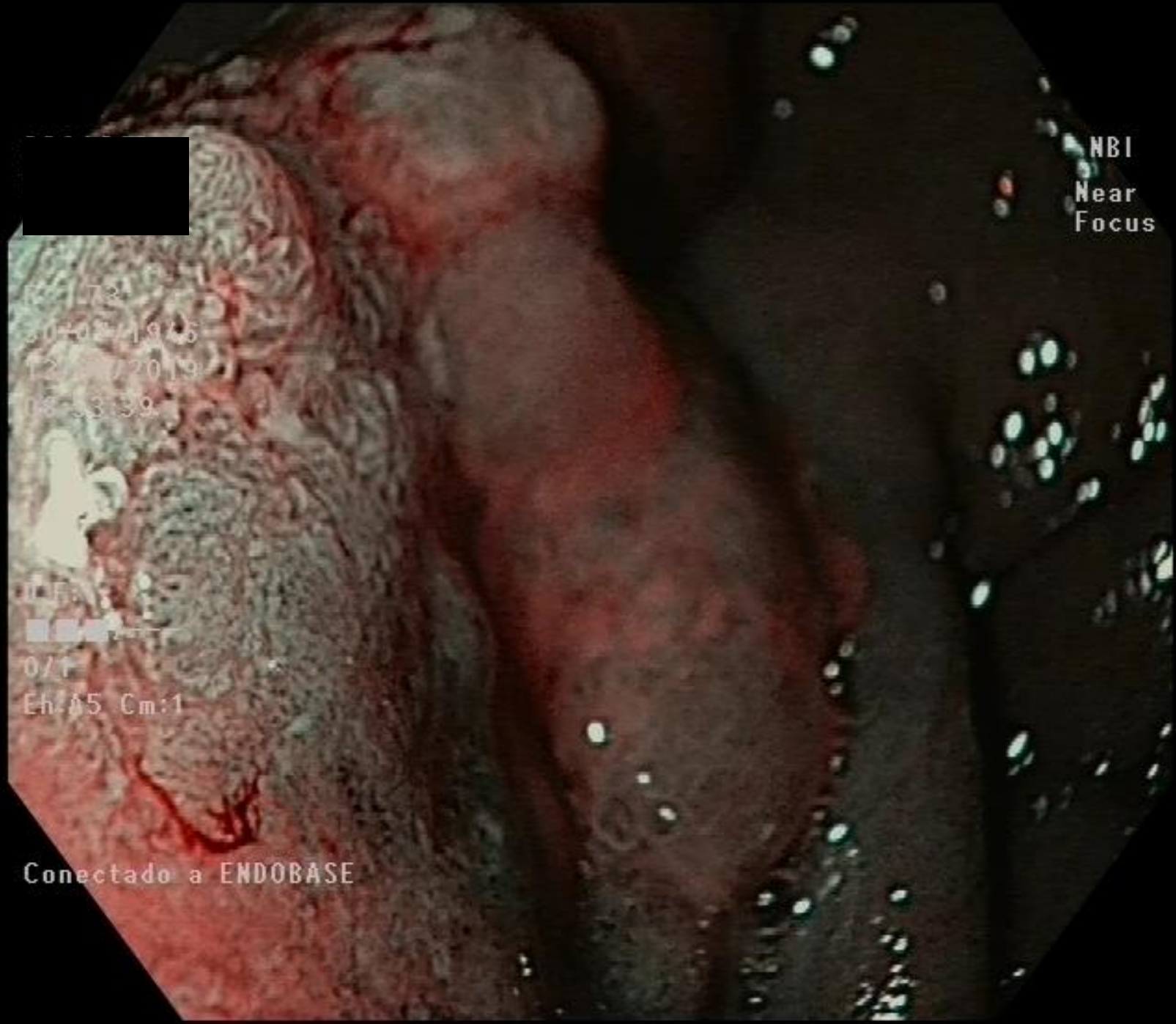


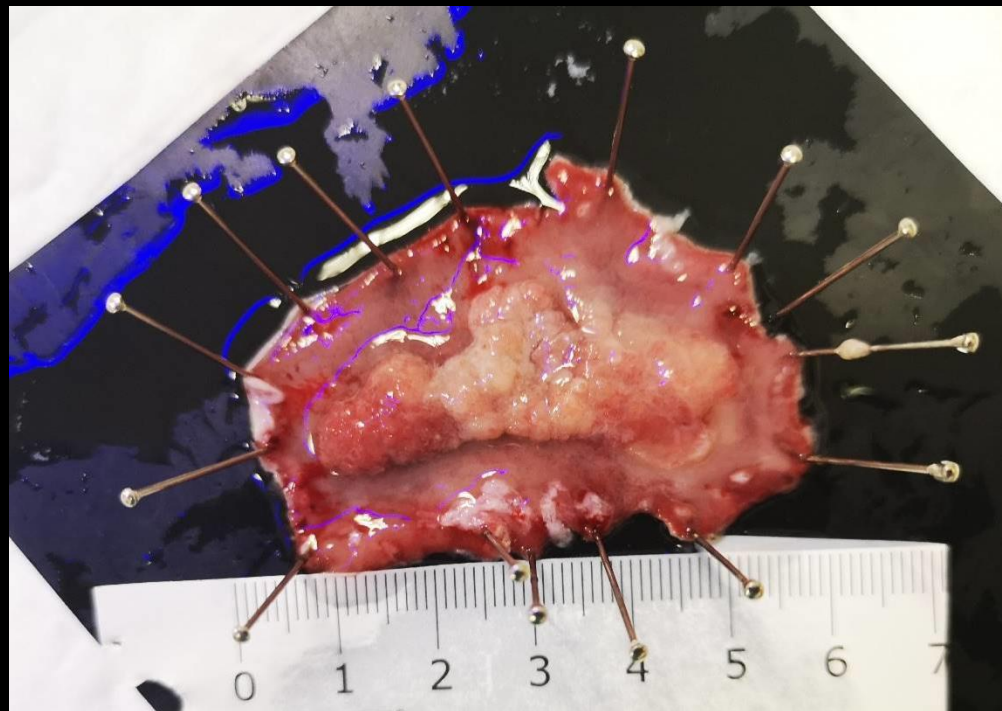
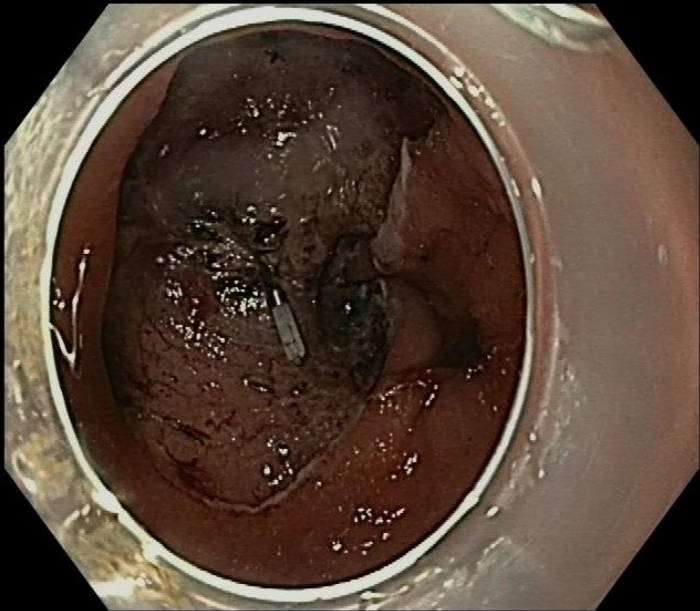
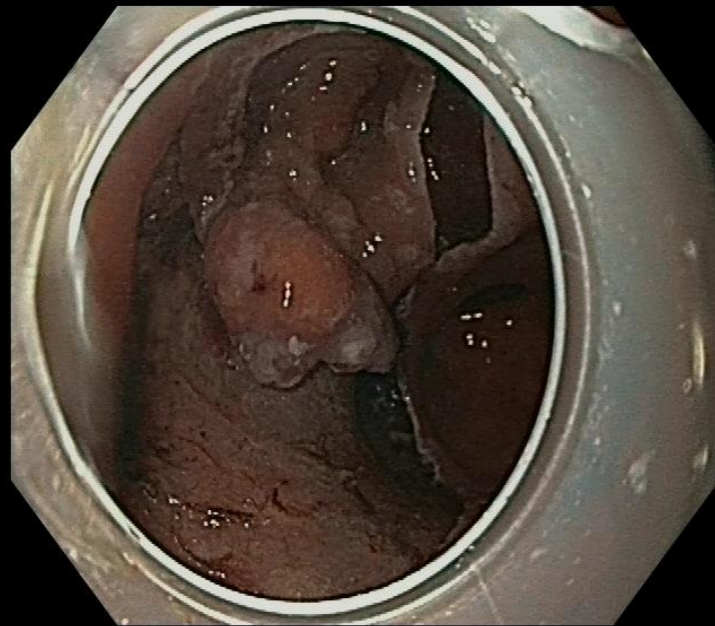
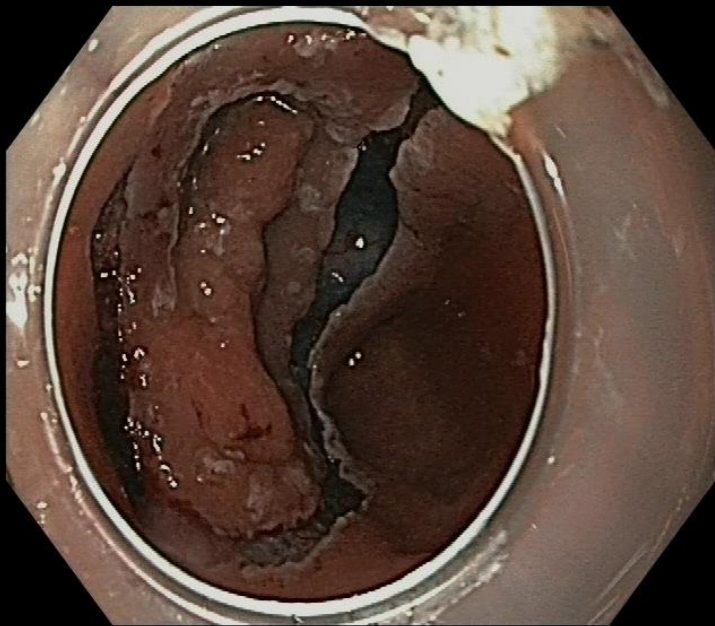
NBI
Near
Focus

73
20-08-1975
12-07-2019
18-3-39

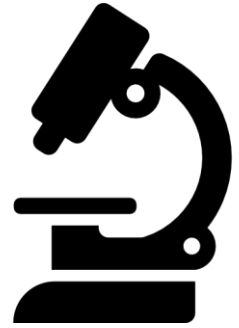ILFA
0/1
Eh:05 Cm:1

Conectado a ENDOBASE





Pathology report



ESD specimen dimensions: 60 x
35 mm

GASTRIC ADENOCARCINOMA. INTESTINAL TYPE (LAUREN'S)

- Lesion size: 45 x 15 mm
- OMS: low grade dysplasia
- Vienna: Category 5
- pT1a
- Margin: R0
- LM - V0 -

Afternoon list

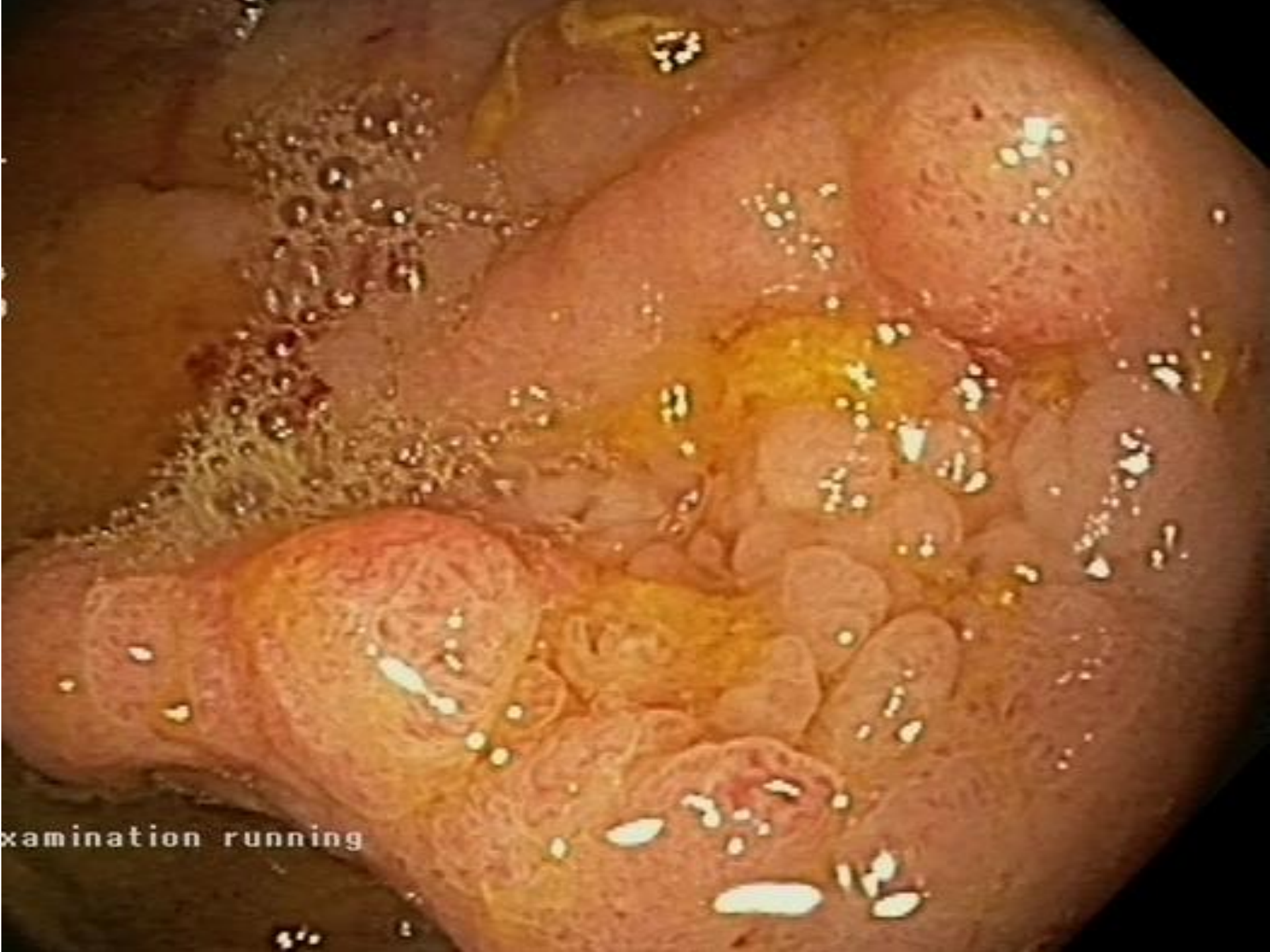Tuesday 1st

Case 6

Endoscopist: Yamamoto

Room 271

- 75yo male
Pulmonary tromboembolism, idiopathic mesenteric thrombosis on Warfarin
NASH
- **LST granular mixed-type (0-IIa+Is)**
 - Estimated lesion size: 35mm
 - Location: hepatic flexure
 - No signs of deep submucosal invasion
 - **Aim:** For en-bloc ESD attempt
- **3 sessile lesions in the ascending and sigmoid colon 10-15mm lesion size**
 - Estimated Lesion size: 35mm
 - **Aim:** For EMR

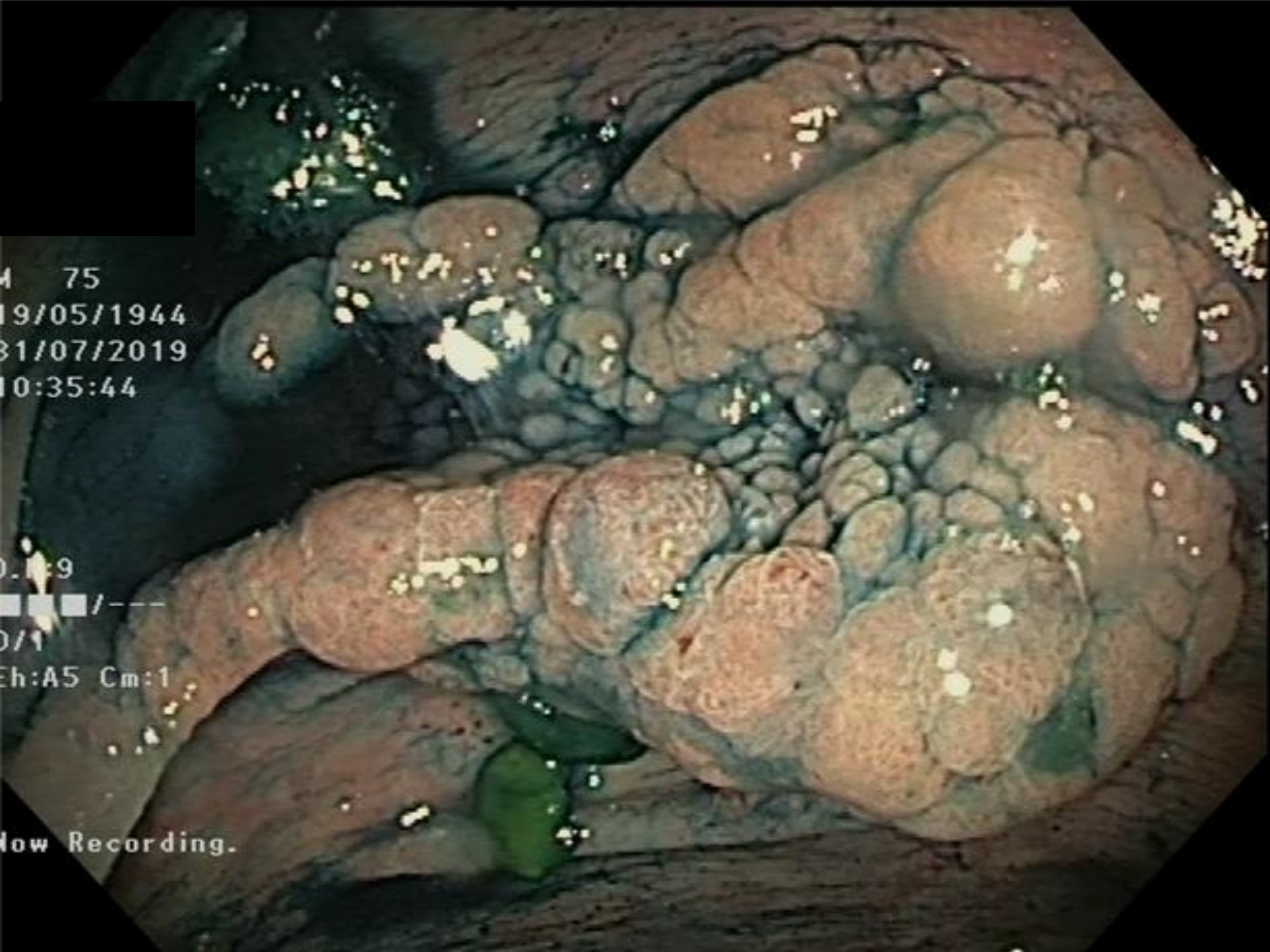

Examination running

4 75
19/05/1944
31/07/2019
10:35:44

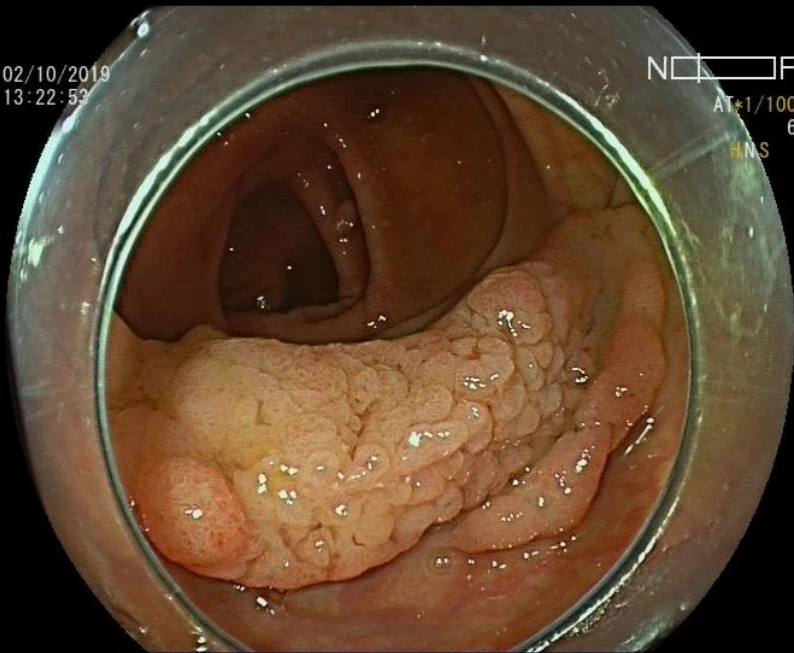
0.1:9
0/1
Eh:A5 Cm:1

low Recording.



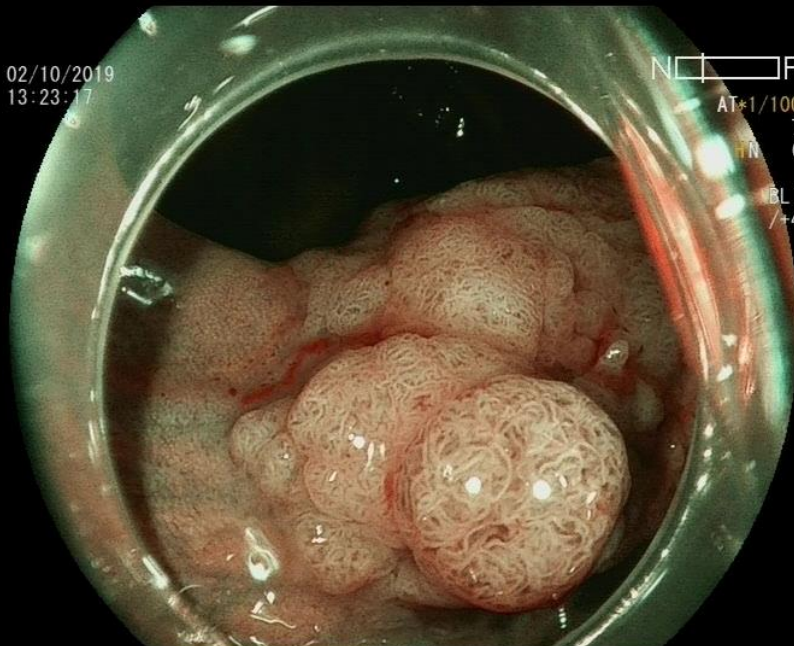02/10/2019
13:22:53

NO [] F
AT#1/100
6
HN S

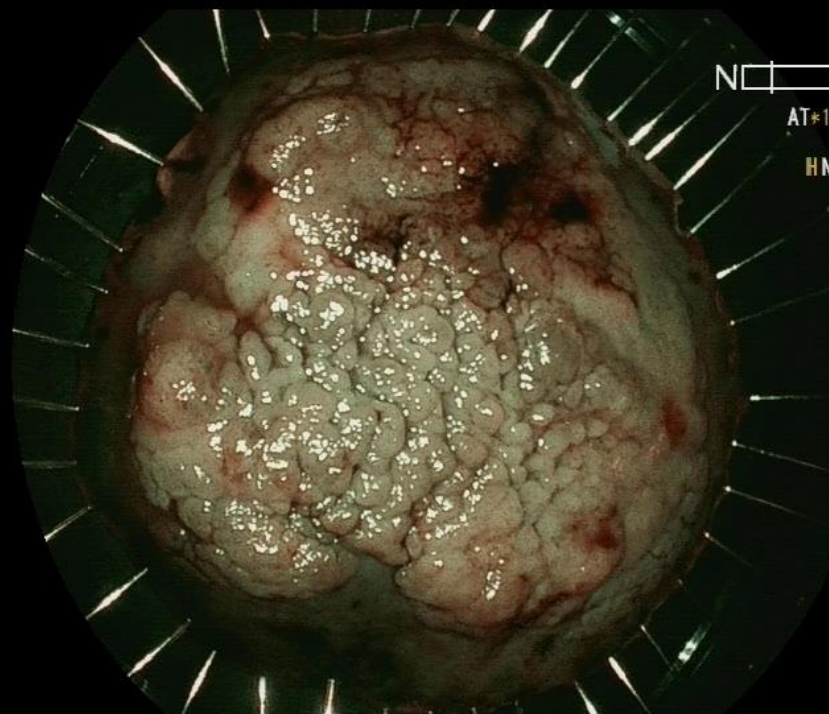


02/10/2019
13:23:17

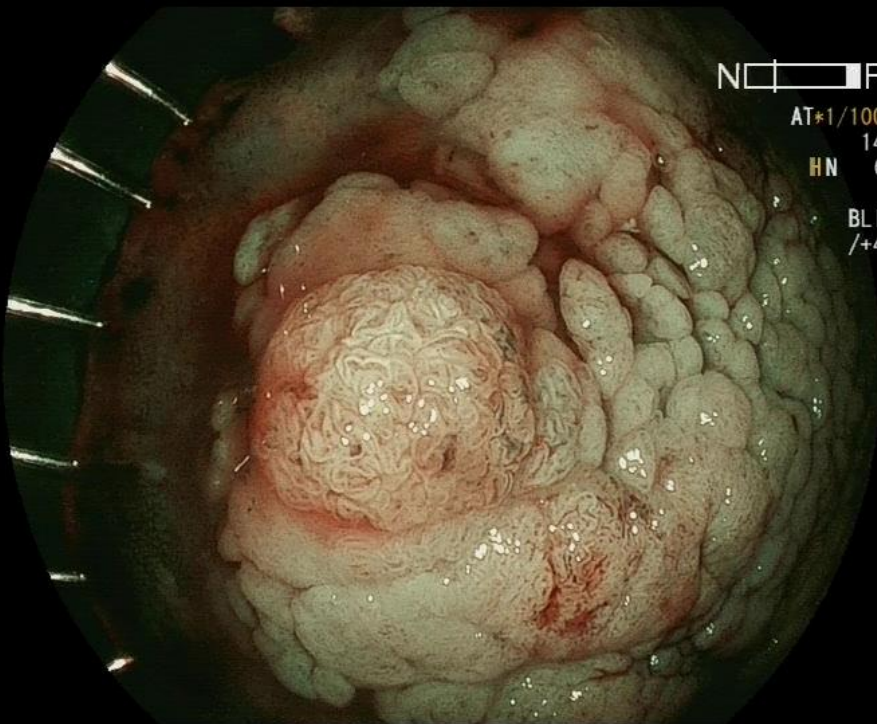
NO [] F
AT#1/100
7
HN C
BLI
/+4



NO [] F
AT#1
HN



NO [] F
AT#1/100
14
HN C
BLI
/+4



Pathology report



TUBULO-VILLOUS ADENOMA

- ESD specimen dimensions: 68 x 60 x 4 mm
- Lesion size: 57 x 50 x 4 mm
- OMS: Low grade dysplasia
- Vienna: Category 3
- Non pedunculated
- Margin: R0 LM-

Case 11

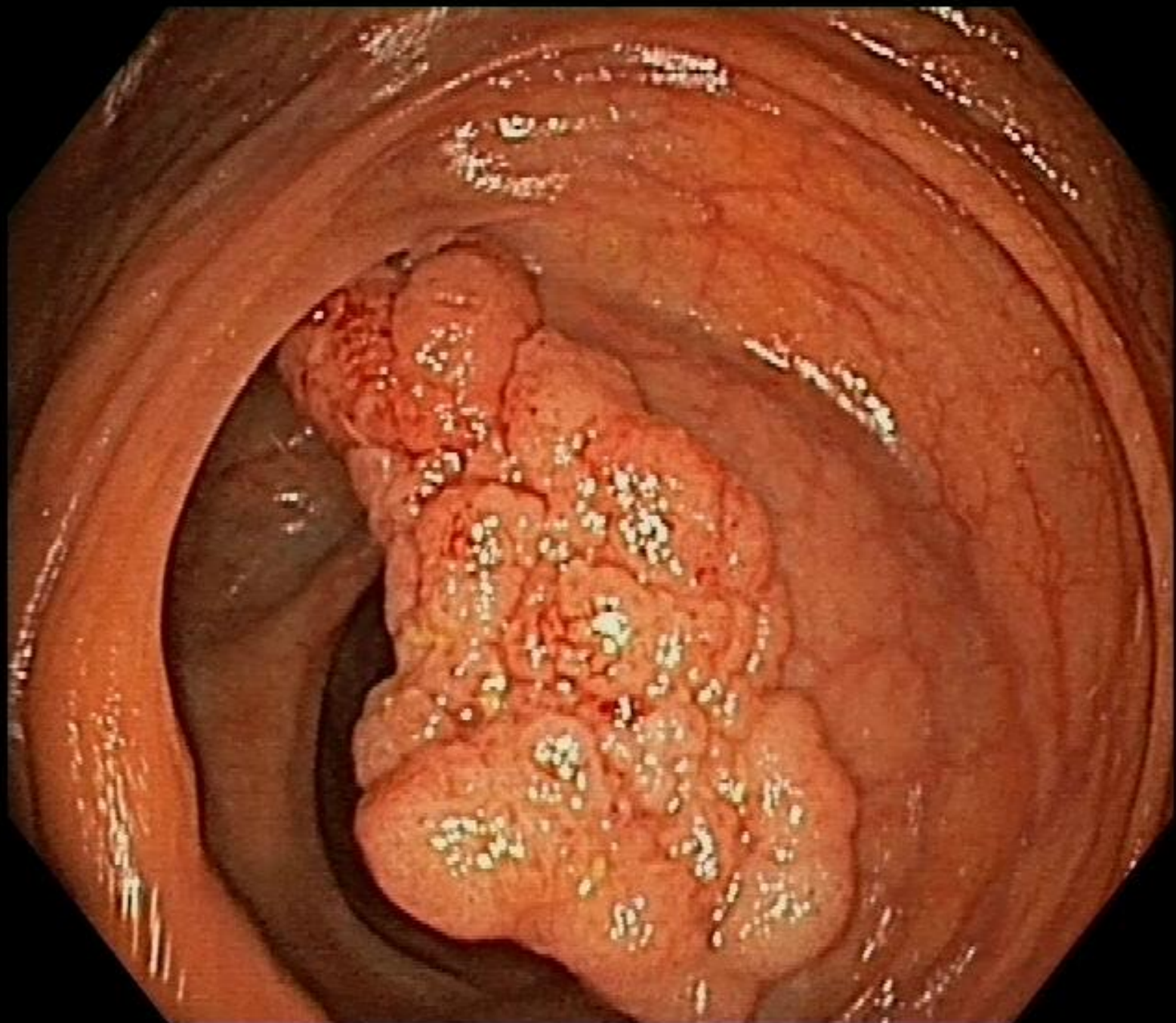
Endoscopist: Maeda

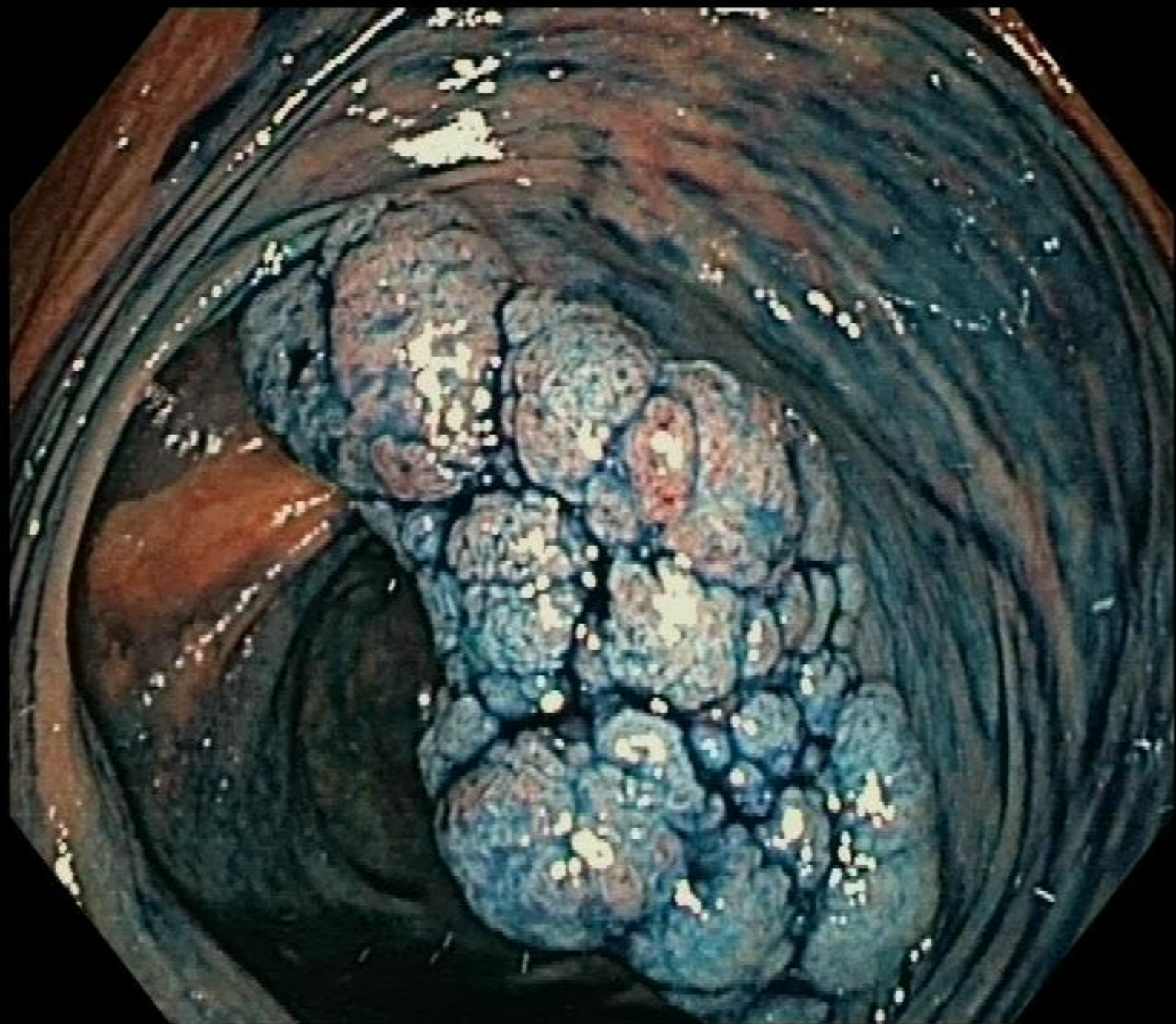
Room 272

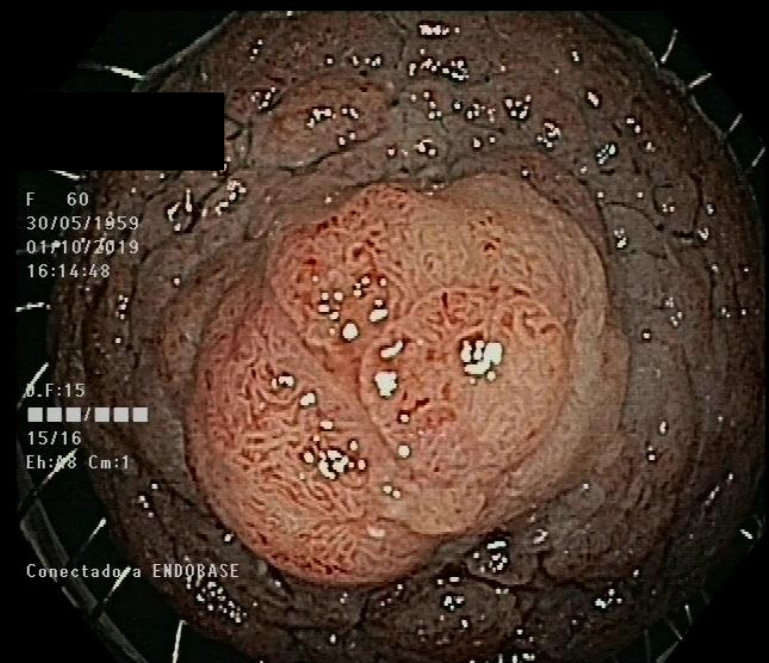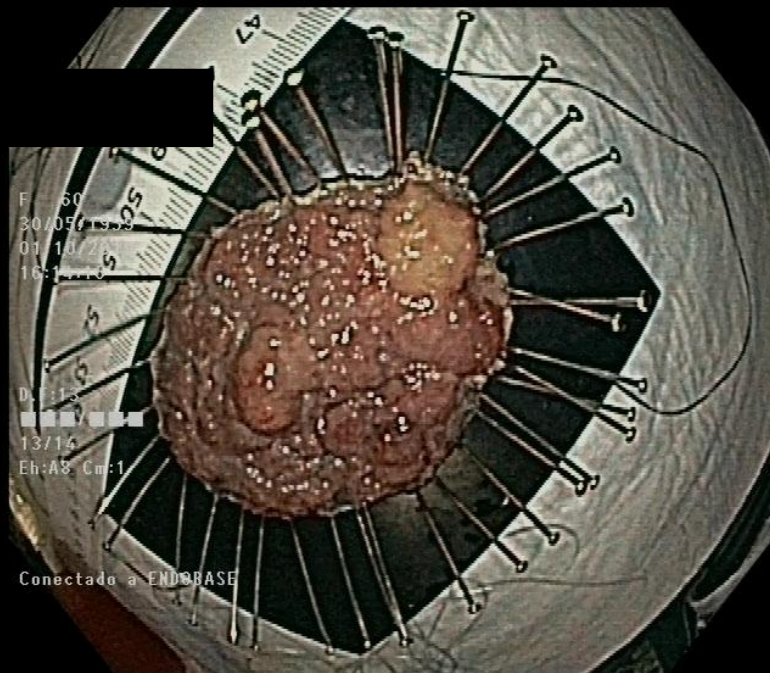
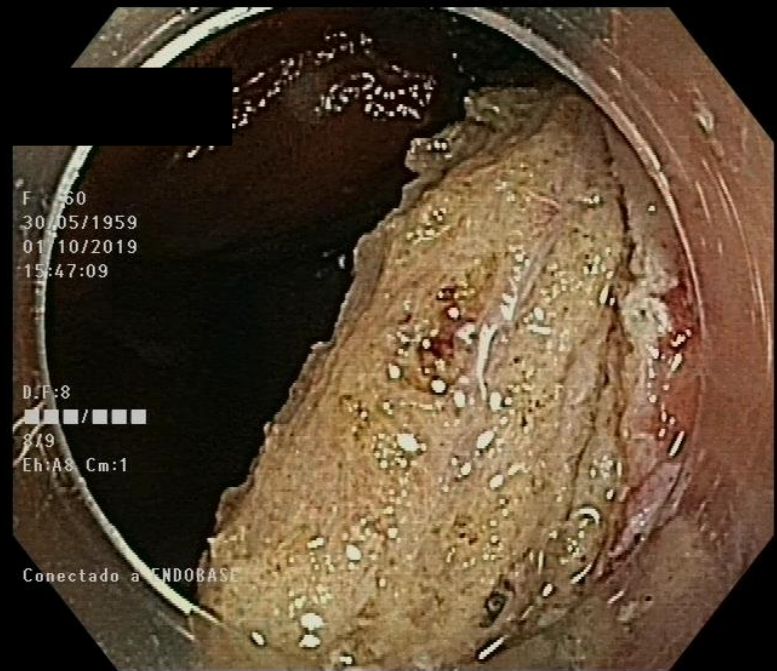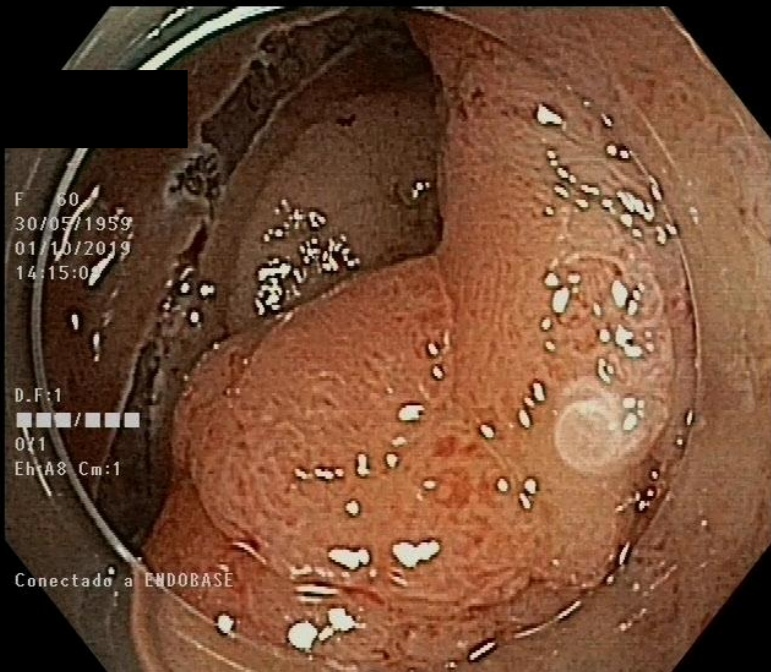- 60yo female

Allergy to salicylates. Rheumatic polymyalgia, currently no treatment.

- **LST granular mixed-type (0-Is+IIa)**
 - Estimated Lesion size: 40mm
 - Location: Ascending colon
 - No signs of deep submucosal invasion
- **Aim:** For en-bloc ESD attempt







Pathology report



TUBULO-VILLOUS ADENOMA

- ESD specimen dimensions: 60 x 45 mm
- Lesion size: 55 x 40 mm
- OMS: Low grade dysplasia
- Vienna: Category 3
- Non pedunculated
- Margin: R0 LM-

SAVE THE DATE!

ESD LIVE MADRID 2020
SPRING EDITION

March 9-10th 2020

Puerta de Hierro University Hospital Majadahonda-Madrid

VISIT

<https://internationalesdlm.wixsite.com/esdlm2020spring>
